

Diagnostic accuracy of power Doppler ultrasound in patients with chronic tennis elbow

C du Toit,¹ M Stieler,² R Saunders,¹ L Bisset,^{3,4} B Vicenzino³

¹ Saunders Sports Medicine, Ipswich, Queensland, Australia;

² Clarke and Robertson Radiology, Pring Street, Queensland, Australia; ³ Division of Physiotherapy, School of Health and Rehabilitation Sciences, University of Queensland, Queensland, Australia; ⁴ School of Physiotherapy and Exercise Science, Griffith University, Queensland, Australia

Correspondence to: Professor B Vicenzino, Division of Physiotherapy, School of Health and Rehabilitation Sciences, University of Queensland, St Lucia, Qld, 4072, Australia; b.vicenzino@uq.edu.au

Accepted 4 February 2008
Published Online First
4 March 2008

ABSTRACT

Objective: To determine the diagnostic accuracy of power Doppler and grey scale ultrasonography, assess the relationship between severity measures and neovascularity, and describe the intra-tendon distribution of neovascularity in chronic tennis elbow.

Design: Between group cross sectional study.

Setting: Sports medicine clinic and radiology centre.

Participants: 32 affected elbows (median and range of duration: 10; 3–120 months) and 18 unaffected contralateral elbows in 25 patients (mean age 50 years) with lateral elbow pain, and 38 unaffected elbows in 19 asymptomatic participants (mean age 45 years) underwent a clinical examination (reference standard test) and grey scale and power Doppler ultrasonographic examination.

Main outcome measures: Ultrasound examination with power Doppler identified neovascularity and grey scale ultrasound changes (lateral epicondyle bony spurring or irregularity, maximum anterior–posterior thickness, and echo characteristics) of the common extensor tendon.

Results: Power Doppler had a strong positive likelihood ratio of 45.39, whereas a combined null finding in power Doppler and grey scale ultrasonography resulted in a robust negative likelihood ratio of 0.05. Grey scale changes were generally not as diagnostically accurate. Common extensor tendon neovascularity was equally distributed between the superficial and deep part of the tendon, and clinical severity measures did not correlate with neovascularity scores.

Conclusions: Neovascularity identified with power Doppler ultrasonography when compared to grey scale changes (alone or in combination with Doppler) was diagnostically superior in identifying chronic tennis elbow. The lack of both neovascularity and grey scale changes on ultrasound examination also substantially increase the probability that the condition is not present and should prompt the clinician to consider other causes for lateral elbow pain.

Tennis elbow affects up to 1.3% of the general population¹ and is a common presentation to primary care medical clinics.² Tendinopathy of the common wrist extensor tendon at the lateral humeral epicondyle is most frequently implicated in tennis elbow, and is usually diagnosed clinically with diagnostic imaging reserved for those cases not responding to conventional treatment modalities.^{3–5}

Grey scale ultrasound changes described with common extensor tendinopathy at the lateral humeral epicondyle are: tendon thickening or thinning, changes in tendon echogenicity, focal tendon areas of hypoechoogenicity, tendon tears, tendon calcifications, or lateral epicondyle bony

spurs or irregularity.^{5–8} Previous reports of the sensitivity and specificity of grey scale ultrasound to diagnose tennis elbow is variable and ranges from 72–88%, and 36–100%, respectively.^{7,8} This large variability of findings in published reports on the sensitivity and specificity of grey scale ultrasonography has been attributed to a high rate of false positive grey scale ultrasound changes.⁸

Recent advances in tendinopathy research have focused on tendon neovascularisation detected with colour/power Doppler ultrasound. The presence of neovessels and accompanying nerves in areas of tendinopathy are associated with increased tendon pain in Achilles, and patellar tendinopathy,^{9–12} and local anaesthetic injections in close vicinity to neovessels have been shown to decrease pain scores in tennis elbow significantly.¹³ Sensory nerve innervation with substance P and calcitonin gene related peptide expression in the extensor carpi radialis brevis tendon in areas of neovascularisation have been implicated as a potential cause of pain in patients with painful tennis elbow.¹⁴ Excellent accuracy has been reported using solely colour Doppler ultrasonography in patients with tennis elbow (sensitivity 95%, specificity 88%),¹⁵ and painful patellar tendinopathy (sensitivity 92%, specificity 100%).¹⁶

Accurate diagnosis of common extensor tendinopathy at the lateral epicondyle as a cause of lateral elbow pain will improve management of this condition, especially in the patient with prolonged symptoms not responding to conventional treatment modalities; conversely the absence of tendinopathy changes will prompt further investigations to identify other possible diagnoses, such as posterior interosseous nerve entrapment or intra-articular abnormalities (for example, elbow and radioulnar osteoarthritis and/or synovitis), or referred pain from the cervical spine.^{5,17} To our knowledge, there are no other studies of the sensitivity and specificity of power Doppler combined with grey scale ultrasound changes in tennis elbow. The aim of this paper was to evaluate the accuracy of power Doppler and grey scale ultrasonography in patients with clinically determined tennis elbow during a single real time ultrasound session. Secondary aims were to: (1) describe the intra-tendon location of neovascularity in the common extensor tendon; (2) evaluate the relationship between clinical measures and intra-tendon neovascularity; and (3) assess the diagnostic accuracy of grey scale ultrasound changes in isolation (for example, differences in diagnostic accuracy for echogenicity, bony spur, side to side difference in tendon thickness) and if a combination of these changes improves accuracy.

PATIENTS AND METHODS

Study population

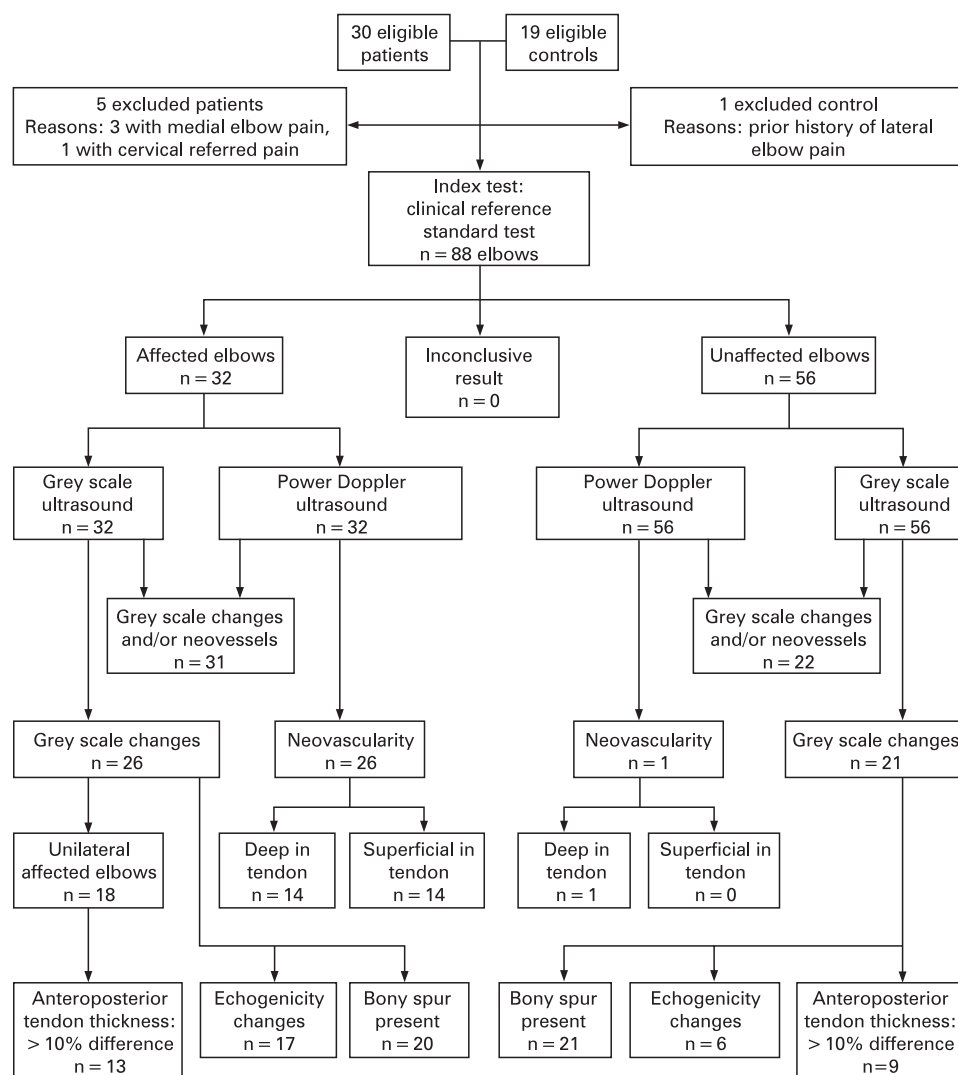
We conducted a cross-sectional study of a group of participants in order to determine the diagnostic accuracy of ultrasound with power Doppler examination for tennis elbow. We recruited a consecutive series of patients who were referred to a private sports medicine clinic (Saunders Sports Medicine, Ipswich, Australia) from general practitioners and sports physicians in the area, or self referred after reading advertisements in the local paper, with a provisional diagnosis of tennis elbow. Inclusion criteria was the presence of lateral elbow pain for more than 3 months, that was exacerbated by activities involving resisted wrist extension and gripping, as reported by the patient, as well as a clinical diagnosis of tennis elbow which included tenderness in the area of the lateral humeral epicondyle, and lateral elbow pain on resisted wrist and/or middle finger extension and gripping.^{3, 5, 18} Exclusion criteria included elbow pain for less than 3 months, limitation of movement with passive forearm pronation, supination, elbow flexion and/or extension that may indicate radioulnar joint osteoarthritis or synovitis, upper limb neurological symptoms or signs that may indicate cervical radiculopathy, and corticosteroid injection into the common extensor tendon within the previous 3 months. Only clinical symptoms and signs were

considered and no other investigations (for example, x ray or nerve conduction studies) were performed. Also included in the study were 19 volunteers with no current or past history of lateral elbow pain. These volunteers were recruited from a general call for volunteers in the same regional location as that of the patients. Inclusion criteria for the control group were that they had no history of elbow pain, no tenderness on palpation of the elbow, full range of motion, with pain-free grip and pain-free resisted wrist extension. Informed consent was obtained from all participants and the ethics committee of the University of Queensland approved the study.

Clinical measures of tennis elbow

Following inclusion into the study the tennis elbow patients completed a 100 point pain and functional limitation visual analogue scale (VAS), as well as grip strength dynamometry (MIE Medical Research Ltd, Leeds, UK).¹⁹ Maximum grip strength was measured on the unaffected side and pain free grip strength was measured on the affected side. The latter required the patient to cease the grip test at the first onset of pain. A standard position of supine, lying with the upper limb by the patient's side with the arm internally rotated such that the palm of the hand faced the examination table, was taken.

Figure 1 Participant flow chart.



Reference standard

Clinical identification of tennis elbow was used as the reference standard²⁰ and each individual elbow was categorised by a medical practitioner undergoing postgraduate training in sports medicine, with 7 years of clinical experience in musculoskeletal medicine (CDT), into one of two groups: affected or unaffected. We chose to use as the reference standard the clinical diagnosis of tennis elbow because it is relatively uncomplicated,³ it is widely adopted in many high quality randomised clinical trials,^{21–23} it has been adopted in studies of outcome measures,^{24–27} and currently there is no better means for diagnosing tennis elbow in clinical practice.

Imaging and interpretation

All ultrasound investigations were performed at Southern X-ray Clinic, Ipswich, Australia. All elbows were examined by one musculoskeletal sonographer (MS) who has postgraduate qualifications and more than 20 years experience in musculoskeletal ultrasonography. There was no blinding of the sonographer as to which elbows were symptomatic in the tennis elbow group; however, the sonographer was blind to the results of the reference standard testing. Ultrasound investigations were performed on the same Philips IU22 ultrasound machine with a high frequency linear area transducer (broad band width transducer with a frequency range of 17–5 MHz). Participants sat with their arm resting on a table, having 90° of elbow flexion and a pronated wrist. The common extensor tendon origin was examined routinely in both longitudinal and transverse planes, with oblique views performed as necessary.

A standardised examination protocol was employed such that the grey scale imaging was first conducted followed by the power Doppler. The grey scale imaging was used to: (1) assess the lateral epicondyle for the presence or absence of bony spurring and or irregularity; (2) measure the maximal anteroposterior thickness of the common extensor tendon; and (3) assess the common extensor tendon for the presence or absence of echogenicity changes—that is, changes in overall echogenicity, homogeneity, and the presence of a tendon tear. The grey scale imaging was then followed by power Doppler imaging, which was performed with a pulse repetition frequency of 1000 Hz, wall filter 75 Hz, colour gain of 86%, and light external probe pressure (not to occlude delicate intra-tendon neovessels). The common extensor tendon was assessed for the presence of intra-tendon neovascularity, interpreted as present when the neovessel diameter was >1 mm. A single frame in which the maximal number of neovessels visible was recorded and off-line analysis (utilising the ImageJ program, US National Institutes of Health, Bethesda, Maryland, USA, <http://rsb.info.nih.gov/ij/>, 1997–2007) was performed on this image to quantify the overall area occupied by the sum of all neovessels visible on the image as a neovascularity score. Intra-tendon neovascularity was then described if present in the deep or superficial part of the tendon. Affected patients without grey

Table 1 Participant characteristics and demographics

	LE (n = 25)	Control (n = 19)
Age in years (mean (SD))	50 (9)	45 (10)
Gender: female	10	10
Duration of symptoms in months (median (min to max))	10 (3 to 120)	NA
Dominant side affected	11	NA
Number with bilateral elbows affected	7	NA

LE, lateral elbow pain group.

scale or power Doppler ultrasonography changes of common extensor tendinopathy were referred for further investigations to consider other causes for lateral elbow pain.

Statistical methods

A number of contingency tables were constructed and included the number of elbows that were either affected or unaffected as determined by the reference standard and positive or negative as determined by the ultrasound derived tests. There were separate contingency tables for power Doppler identified neovascularisation, individual grey scale changes (echogenicity changes, bony spurring or irregularity, or anteroposterior thickness side to side difference of more than 10% as described by Connell *et al*²⁸), combined grey scale changes, and grey scale and power Doppler changes combined. These contingency tables were then analysed using InStat 3 for Macintosh (GraphPad Software Inc, San Diego, California, USA) to derive point estimates of accuracy (sensitivity, specificity, positive predictive value and negative predictive value) and their 95% confidence intervals. Likelihood ratios were then calculated from these estimates by using the methods described previously.^{28 29}

Simple t tests were used to assess differences (at 95% confidence level) in baseline patient characteristics between the tennis elbow group and the asymptomatic group. Pearson's correlation statistic was used to test the degree of relationships between neovascularity score and the clinical measures of pain and function VAS and pain free grip strength.

RESULTS

Participants

Thirty patients were referred (20 from general practitioners, two from sports physicians, and eight self referred) to the study over a 6 month period from January to June 2005. The flow of participants through the study is shown in fig 1. Five patients were excluded from the study, which left 25 participants (10 female) aged between 32–67 years (mean (SD) 50 (9) years) with a mean duration of symptoms of 27 (38) months (range 3–120 months) in the study. On average the patients had a mean pain VAS of 61 (25.4) mm, function VAS of 55.4 (19.8) mm, pain free grip strength of 120.3 (72.3) N and maximum grip strength of 329.3 (88) N. Nineteen asymptomatic participants (10 female) aged between 30–67 years (mean 45 (10)) were also studied prospectively. In total, this amounted to 32 affected elbows (that is, seven patients had bilateral tennis elbow) and 56 unaffected elbows. There were no significant differences in patient characteristics and demographics between the two groups (table 1).

Table 2 Number of affected and unaffected elbows with ultrasound changes

Test	Affected (n = 32)		Unaffected (n = 56)	
	Present (%)	Absent (%)	Present (%)	Absent (%)
Neovascularity	26 (81.3)	6 (18.8)	1 (1.8)	55 (98.2)
Grey scale changes	26 (81.3)	6 (18.8)	21 (37.5)	35 (62.5)
Neovascularity and/or grey scale changes	31 (96.8)	1 (3.2)	22 (39.2)	34 (60.7)
Break down of grey scale changes				
Echo changes	17 (53.1)	15 (46.9)	6 (10.7)	50 (89.3)
Bony spur	20 (62.5)	12 (37.5)	21 (37.5)	35 (62.5)
Thickness*	13 (72.2)	5 (27.8)	9 (47.4)	10 (52.6)

*Side to side comparison in patients with unilateral symptoms. Affected n = 18, unaffected n = 19.

Table 3 Diagnostic accuracy indices expressed as percentages (95% confidence intervals) for the findings present on ultrasound examination with and without power Doppler study

Present	Sensitivity	Specificity	PPV	NPV	Positive LR	Negative LR
Neovascularity	81 (60 to 90)	98 (90 to 100)	96 (60 to 90)	90 (80 to 100)	45.39*	0.19
Grey scale changes	81 (60 to 90)	63 (50 to 80)	55 (40 to 70)	85 (70 to 90)	2.17	0.30
Neovascularity and/or grey scale changes	97 (80 to 100)	61 (50 to 70)	58 (40 to 70)	97 (90 to 100)	2.47	0.05*
Break down of grey scale changes						
Echo changes	53 (30 to 70)	89 (80 to 100)	74 (50 to 90)	77 (60 to 90)	4.96	0.53
Bony spur	63 (40 to 80)	63 (50 to 80)	49 (30 to 60)	75 (60 to 90)	1.67	0.60
Tendon thickness†	72 (50 to 90)	52 (30 to 80)	59 (40 to 90)	67 (40 to 90)	1.53	0.53

LR, likelihood ratio; NPV, negative predictive value, PPV, positive predictive value.

*Generates large and often conclusive shifts in probability.²⁸

†10% difference in thickness between affected and unaffected side.

Test results and accuracy

For each participant the standard reference testing and ultrasound examination was conducted within an hour of each other. Data are presented as numbers and relevant proportions (%) of cases that have ultrasound findings in table 2. Estimates of diagnostic accuracy and their 95% confidence intervals are shown in table 3. Both Doppler and grey scale measures were sensitive when considered in isolation and when used together (81–97%) but only neovascularisation was highly specific (98%). These indices of accuracy were reflected in a high positive likelihood ratio (45.39) for power Doppler and a low negative likelihood ratio (0.05) for a combined power Doppler and grey scale test.

With the exception of the specificity of echogenicity changes, which was 89%, the estimates of diagnostic accuracy were poor for separate grey scale measures (that is, 52–72%).

There was no difference in the distribution of neovessels between the superficial (12 elbows) and deep portions (14 elbows) of the common extensor tendon. The mean (SD) neovascularity score was 3.4 (3.9) mm². The neovascularity score and the clinical measures of tennis elbow (pain and function VAS and grip strength) were not correlated (Pearson's $r < 0.2$).

There were no reported adverse effects with ultrasound and standard reference testing and no participant was lost to testing.

DISCUSSION

The primary aim of this study was to evaluate the comparative diagnostic accuracy of power Doppler and grey scale ultrasonography during a single real-time ultrasound session. On balance our data show that power Doppler ultrasonography appears to hold the highest diagnostic accuracy for chronic tennis elbow. Power Doppler detected neovascularity reflects a conclusive shift in probability for the diagnosis of chronic tennis elbow—that is, finding neovascularisation in the common extensor tendon substantially increases the pre-test probability of the condition being present from a prevalence of 1.3% in the general population¹ to a post-test probability of 37.4%. Thirty-one of 32 affected elbows had grey scale changes and/or power Doppler detected neovascularity. There was only one affected elbow without grey scale changes or power Doppler detected neovascularity. This patient subsequently had further radiological investigations performed, which showed radio-capitellar osteoarthritic changes as a cause for lateral elbow pain. This reflects the finding of a very low negative likelihood ratio, which shifts the post-test probability to 0.07% (from a prevalence of 1.3%)—that is, a negative finding on both power Doppler and

grey scale ultrasound will conclusively rule out tennis elbow as a diagnosis, and should prompt the clinician to perform further investigations.

Changes on both grey scale and power Doppler ultrasonography combined were most sensitive (97%), and power Doppler alone was most specific (98%) for the diagnosis of tennis elbow. No previous studies have reported the diagnostic accuracy for both grey scale and power Doppler in patients with clinically determined tennis elbow. However, several have reported findings in either Doppler or grey scale ultrasonography.^{7–15} Our results for power Doppler sensitivity (table 3) is slightly lower than the previously reported sensitivity of 95% for this condition, but specificity was comparable to previous data.¹⁵ Grey scale ultrasound accuracy in the current study (sensitivity 81%, specificity 63%) is comparable to previously reported sensitivities and specificities: 72–88% and 36–100%, respectively.^{7–8}

A secondary aim of this study was to evaluate the diagnostic accuracy of grey scale ultrasonography, both in terms of individual findings (lateral epicondyle bony spurring or irregularity, maximum anterior–posterior thickness, and echo characteristics) and combined findings. Grey scale changes in isolation showed moderate diagnostic accuracy with sensitivity ranging from 53% for echogenicity changes to 72% for side-to-side difference in tendon thickness (>10% difference). Specificity ranged from 52% for tendon thickness differences to 89% for echogenicity. Sensitivity increased to 81% when grey scale changes were considered in combination, but specificity remained at a moderate 63%.

In keeping with similar studies on Achilles and patellar tendinopathy,^{30–31} we did not find a correlation between pain severity (as indicated by pain and function VAS and grip strength) and the amount of neovascularity as opposed to the presence of neovessels.

Interestingly, we identified a small subgroup of patients (five) with neovessels in the presence of no structural changes, which has not been reported elsewhere. In seeking to explain this novel finding we feel that consideration needs to be given to the fact that our paper is the first to report findings from power Doppler in tennis elbow, and that the underlying pathological processes for neovessels and structural changes are likely different and possibly independent in some patients. This subgroup requires further study in order to understand the underlying pathology in tennis elbow better.

A limitation of this study is that we only had one ultrasonographer to report on the ultrasound changes, and that while he was blinded to the clinical examination findings he was not blinded to the symptomatic elbows. Because the identification of the neovessels with power Doppler

What is already known on this topic

- ▶ Neovascularity is associated with pain in tennis elbow (as well as Achilles and patellar tendinopathy).
- ▶ Colour Doppler ultrasonography has high diagnostic accuracy in tennis elbow.
- ▶ Grey scale changes have variable accuracy levels.

What this study adds

- ▶ Power Doppler ultrasonography has superior diagnostic accuracy for identifying cases of tennis elbow.
- ▶ Ruling out tennis elbow is best accomplished with combined power Doppler and grey scale ultrasonography.
- ▶ Intra-tendon neovascularity occurs with painful tennis elbow, but clinical severity measures do not correlate with the amount of neovascularity.

ultrasonography can only be assessed during real time ultrasound and that this study was conducted under regular clinical conditions (that is, suburban radiography clinic with only one ultrasonographer on duty), it was practically difficult to evaluate inter-rater reliability of this measure, which is a consideration that the reader needs to make on interpreting our findings.

In our study only power Doppler ultrasonography was used because it is our opinion that power Doppler displays vascularity better in low flow states such as in common extensor tendinopathy at the lateral epicondyle, but this requires further investigation. Notwithstanding this, others have reported equal diagnostic accuracy of colour and power Doppler ultrasonography, but that was in painful Achilles tendinopathy.¹²

Conclusions

Our study found excellent diagnostic accuracy of power Doppler ultrasonography for ruling in cases with lateral elbow pain, whereas the absence of tendon neovascularity and grey scale ultrasound changes should raise the question of an alternative cause for lateral elbow pain than extensor tendinopathy.

Funding: Financial support from The University of Queensland and National Health and Medical Research Council of Australia (Primary Care Research): project number: 252710

Competing interests: None.

Patient consent: Obtained.

REFERENCES

1. **Shiri R**, Viikari-Juntura E, Varonen H, *et al*. Prevalence and determinants of lateral and medial epicondylitis: a population study. *Am J Epidemiol* 2006;**164**:1065–74.
2. **Verhaar JAN**. Tennis elbow – anatomical, epidemiologic and therapeutic aspects. *Int Orthop* 1994;**18**:263–7.
3. **Haker E**. Lateral epicondylalgia: diagnosis, treatment and evaluation. *Crit Rev Phys Rehabil Med* 1993;**5**:129–54.
4. **Vicenzino B**, Wright A. Lateral epicondylalgia I: a review of epidemiology, pathophysiology, aetiology and natural history. *Phys Ther Rev* 1996;**1**:23–34.
5. **Connell D**, Burke F, Coombes P, *et al*. Sonographic examination of lateral epicondylitis. *AJR Am J Roentgenol* 2001;**176**:777–82.
6. **Maffulli N**, Regine R, Carrillo F, *et al*. Tennis elbow: an ultrasonographic study in tennis players. *Br J Sports Med* 1990;**24**:151–5.
7. **Miller TT**, Shapiro MA, Schultz E, *et al*. Comparison of sonography and MRI for diagnosing epicondylitis. *J Clin Ultrasound* 2002;**30**:193–202.
8. **Levin D**, Nazarian LN, Miller TT, *et al*. Lateral epicondylitis of the elbow: US findings. *Radiology* 2005;**237**:230–4.
9. **Alfredson H**, Ohberg L, Forsgren S. Is vasculo-neural ingrowth the cause of pain in chronic Achilles tendinosis? An investigation using ultrasonography and colour Doppler, immunohistochemistry, and diagnostic injections. *Knee Surg Sports Traumatol Arthrosc* 2003;**11**:334–8.
10. **Zanetti M**, Metzdorf A, Kundert HP, *et al*. Achilles tendons: clinical relevance of neovascularization diagnosed with power Doppler US. *Radiology* 2003;**227**:556–60.
11. **Cook JL**, Malliaras P, De Luca J, *et al*. Neovascularization and pain in abnormal patellar tendons of active jumping athletes. *Clin J Sport Med* 2004;**14**:296–9.
12. **Reiter M**, Ulreich N, Dirisamer A, *et al*. Colour and power Doppler sonography in symptomatic Achilles tendon disease. *Int J Sports Med* 2004;**25**:301–5.
13. **Zeisig E**, Ohberg L, Alfredson H. Extensor origin vascularity related to pain in patients with tennis elbow. *Knee Surg Sports Traumatol Arthrosc* 2006;**14**:659–63.
14. **Ljung BO**, Forsgren S, Friden J. Substance P and calcitonin gene-related peptide expression at the extensor carpi radialis brevis muscle origin: implications for the etiology of tennis elbow. *J Orthop Res* 1999;**17**:554–9.
15. **Torp-Pedersen T**, Torp-Pedersen S, Bliddal H. Diagnostic value of ultrasonography in epicondylitis. *Ann Intern Med* 2002;**136**:781–2.
16. **Weinberg EP**, Adams MJ, Hollenberg GM. Color Doppler sonography of patellar tendinosis. *AJR Am J Roentgenol* 1998;**171**:743–4.
17. **Nirschl RP**, Ashman ES. Elbow tendinopathy: tennis elbow. *Clin Sports Med* 2003;**22**:813.
18. **Vicenzino B**. Lateral epicondylalgia: a musculoskeletal physiotherapy perspective. *Man Ther* 2003;**8**:66–79.
19. **Bisset L**, Paungmalai A, Vicenzino B, *et al*. A systematic review and meta-analysis of clinical trials on physical interventions for lateral epicondylalgia. *Br J Sports Med* 2005;**39**:411–22.
20. **Bossuyt PM**, Reitsma JB, Bruns DE, *et al*. Towards complete and accurate reporting of studies of diagnostic accuracy: the STARD initiative. *BMJ* 2003;**326**:41–4.
21. **Bisset L**, Beller E, Jull G, *et al*. Mobilisation with movement and exercise, corticosteroid injection, or wait and see for tennis elbow: randomised trial. *BMJ* 2006;**333**:939.
22. **Hay EM**, Paterson SM, Lewis M, *et al*. Pragmatic randomised controlled trial of local corticosteroid injection and naproxen for treatment of lateral epicondylitis of elbow in primary care. *BMJ* 1999;**319**:964–8.
23. **Smidt N**, van der Windt D, Assendelft WJJ, *et al*. Corticosteroid injections, physiotherapy, or a wait-and-see policy for lateral epicondylitis: a randomised controlled trial. *Lancet* 2002;**359**:657–62.
24. **Pienimäki T**, Siira P, Vanharanta H. Muscle function of the hand, wrist and forearm in chronic lateral epicondylitis. *Eur J Phys Med Rehabil* 1997;**7**:171–8.
25. **Pienimäki T**, Vanharanta H. Pain questionnaire, pain drawing and pressure pain thresholds in chronic lateral epicondylitis. *Eur J Phys Med Rehabil* 1998;**8**:3–9.
26. **Stratford P**, Levy D, Gowland C. Evaluative properties of measures used to assess patients with lateral epicondylitis at the elbow. *Physiother Can* 1993;**45**:160–4.
27. **Smidt N**, van der Windt DA, Assendelft WJJ, *et al*. Interobserver reproducibility of the assessment of severity of complaints, grip strength, and pressure pain threshold in patients with lateral epicondylitis. *Arch Phys Med Rehabil* 2002;**83**:1145–50.
28. **Hayden SR**, Brown MD. Likelihood ratio: a powerful tool for incorporating the results of a diagnostic test into clinical decision making. *Ann Emerg Med* 1999;**33**:575–80.
29. **Cleland J**. *Orthopaedic clinical examination: an evidence-based approach for physical therapists*. Icon Learning Systems, 2005.
30. **Vos R-J**, Weir A, Cobben LPJ, *et al*. The value of power Doppler ultrasonography in Achilles tendinopathy: a prospective study. *Am J Sports Med* 2007;**35**:1696.
31. **Cook JL**, Malliaras P, De Luca J, *et al*. Vascularity and pain in the patellar tendon of adult jumping athletes: a 5 month longitudinal study. *Br J Sports Med* 2005;**39**:458–61.