

# An unusual case of stent thrombosis: a case report

Atifur Rahman<sup>1,2,\*</sup> and Sophia Wong <sup>1</sup>

<sup>1</sup>Department of Cardiology, Gold Coast University Hospital, 1 Hospital Blvd, Southport, Queensland 4215, Australia; and <sup>2</sup>Griffith University School of Medicine, Queensland, Australia

Received 30 December 2018; first decision 16 January 2019; accepted 23 June 2019; online publish-ahead-of-print 13 July 2019

## Background

Stent thrombosis is a serious and potentially life-threatening complication of percutaneous coronary intervention. It often presents dramatically, typically resulting in ST-elevation myocardial infarction which is associated with a high mortality rate. Premature discontinuation of antiplatelet therapy in the initial 30 days after stenting is arguably the most important predictor of stent thrombosis. In some cases, discontinuation of therapy is unintentional, such as in patients with short-bowel length or malabsorption syndromes.

## Case summary

A 70-year-old man presented to our hospital with stent thrombosis due to non-absorption of antiplatelet agents, 3 days after an elective percutaneous intervention to the right coronary artery. The patient, who had had a laparoscopic high anterior resection due to previous colorectal cancer, had noticed tablets passing whole into his colostomy bag. Repeat balloon angioplasty and stenting were performed and the patient received further antiplatelet therapy in a crushed form.

## Discussion

Drug absorption in the gastrointestinal tract is altered when a significant length of the gut has been resected. Reduced intestinal luminal transit time and insufficient contact time with intestinal mucosa leads to reduced bio-availability of drugs and increased risk of stent thrombosis. The aetiology of stent thrombosis can be investigated with intravascular imaging techniques and platelet function testing. Management includes using different drug formulations and doses and monitoring the outcomes of therapy. In some cases, it may also be appropriate to involve a gastroenterology team, preferably in the multidisciplinary environment of an intestinal rehabilitation centre.

## Keywords

Stent thrombosis • Stent failure • Drug malabsorption • Antiplatelet therapy • Case report

## Learning points

- Stent thrombosis remains an important complication of percutaneous coronary intervention. One of the most significant predictive factors for stent thrombosis is the premature cessation of antiplatelet therapy.
- Patients presenting with reduced bowel length or malabsorption syndromes may not be able to absorb essential antiplatelet therapy after percutaneous coronary intervention.
- A potential solution to this is the use of different formulations and doses of drugs, such as using drugs in the crushed form.

\* Corresponding author. Tel: +61 07 5687 4910, Fax: +61 07 5697 4696, Email: [Atifur.Rahman@health.qld.gov.au](mailto:Atifur.Rahman@health.qld.gov.au)

Handling Editor: Thomas Johnson

Peer-reviewer: Domenico D'Amario

Compliance Editor: Rahul Mukherjee

Supplementary Material Editor: Vishal Shahil Mehta

© The Author(s) 2019. Published by Oxford University Press on behalf of the European Society of Cardiology.

This is an Open Access article distributed under the terms of the Creative Commons Attribution Non-Commercial License (<http://creativecommons.org/licenses/by-nc/4.0/>), which permits non-commercial re-use, distribution, and reproduction in any medium, provided the original work is properly cited. For commercial re-use, please contact [journals.permissions@oup.com](mailto:journals.permissions@oup.com)

## Introduction

Bare-metal stents (BMS) and drug-eluting stents (DES) are widely used in the management of coronary artery disease. Two major causes of stent failure include stent thrombosis (ST) and in-stent restenosis (ISR).

In-stent restenosis is the gradual narrowing of a stent lumen, secondary to neo-intimal hyperplasia. It usually results in stable angina. The inflammatory response to vessel wall injury during angioplasty plays a central role in ISR, with vessel wall inflammation driving fibroblast growth and smooth muscle cell hyperplasia.<sup>1</sup> Angiographic follow-up has demonstrated that neo-intimal hyperplasia results in ISR in ~30.1% of cases after intervention with BMS.<sup>2</sup> With contemporary DES, clinically relevant restenosis occurs in <5% of cases at 12 months.<sup>3</sup> Drug-eluting stents have the added advantage of releasing an anti-proliferative drug that reduces neointimal proliferation, thus resulting in lower rates of ISR.

ST is a serious and potentially life-threatening complication after percutaneous coronary intervention. Stent thrombosis is often a dramatic event, typically resulting in ST-elevation myocardial infarction which has a high mortality rate.<sup>4</sup> Stent thrombosis can occur early, that is, within 30 days, or late, beyond 30 days. In general, early ST is more common, accounting for 50–70% of all cases.<sup>5,6</sup> A recent study of a registry of 18 334 patients demonstrated that the cumulative incidence of definite stent thrombosis at 3 years was 1.5% with a BMS, 2.2% with first-generation DES, and 1.0% with second-generation DES.<sup>7</sup>

Risk factors associated with ST can be categorized into clinical, angiographic, and procedural factors. Clinical factors include non-compliance to medical therapy, diabetes, renal failure, young age, smoking, presence of malignancy, and stenting for myocardial infarction (primary angioplasty). Angiographic factors include small vessel diameter, the use of long stents and multivessel disease. Procedural factors include undersizing of a stent, bifurcation stenting, and dissection. Of these, premature cessation of antiplatelet therapy within the first 30 days after stenting is arguably the most important predictor of ST.<sup>8</sup>

We present the case of a patient who developed stent thrombosis due to non-absorption of antiplatelet agents, 3 days after elective percutaneous intervention to the right coronary artery (RCA).

## Timeline

Day 1	Elective uncomplicated angioplasty with drug-eluting stents deployed to proximal and mid-right coronary artery (RCA)
Day 2-3	Patient notices whole tablets in colostomy bag, 2–3 h after ingestion
Day 4	Presentation with ST-elevation myocardial infarction, leading to cardiac arrest Urgent coronary angiogram revealed stent thrombosis of the RCA Balloon dilatation and stenting performed successfully Antiplatelet therapy now administered in crushed form, following diagnosis of stent thrombosis.

## Case presentation

Our patient was a 70-year-old man who had undergone elective percutaneous intervention to the RCA. The patient's past medical history included atrial fibrillation and adenocarcinoma of the colon with hepatic metastases, for which he had a laparoscopic high anterior resection and colostomy formation 2 years prior.

Elective uncomplicated angioplasty was performed using drug-eluting stents to the proximal and mid-RCA with satisfactory result. This included adequate post-dilatation after stenting, resulting in no residual stenosis. The patient was subsequently discharged on triple therapy, including rivaroxaban, aspirin, and clopidogrel.

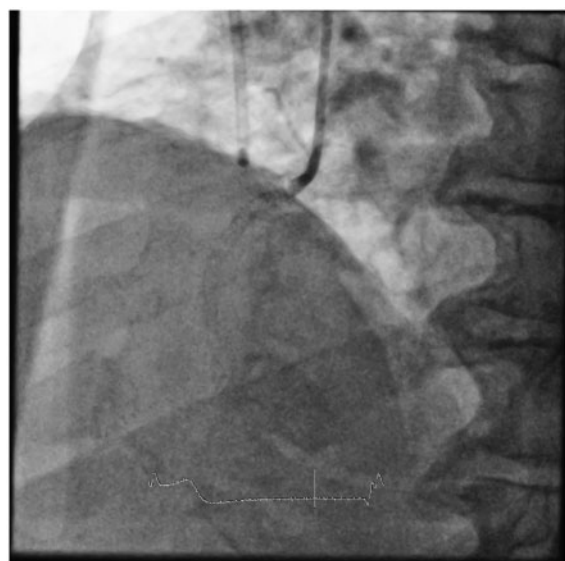Three days after the elective procedure, the patient returned to the hospital with severe central crushing chest pain. On examination his heart sounds were dual with no additional murmurs. His chest was clear on auscultation. The jugular venous pressure was not raised and there was no signs of decompensated heart failure. An electrocardiogram demonstrated inferior ST-segment elevation. He subsequently had a cardiac arrest from which he was successfully resuscitated.

Urgent coronary angiogram revealed thrombotic occlusion of the RCA at the ostium, with TIMI 0 flow (*Figure 1*). Balloon dilatation and subsequent stenting were performed successfully to achieve TIMI III flow with satisfactory result (*Figure 2*). Although intravascular imaging techniques such as optical coherent tomography (OCT) or intravascular ultrasound (IVUS) were not performed, angiographically there was no stent edge dissection and the stent appeared adequately dilated.

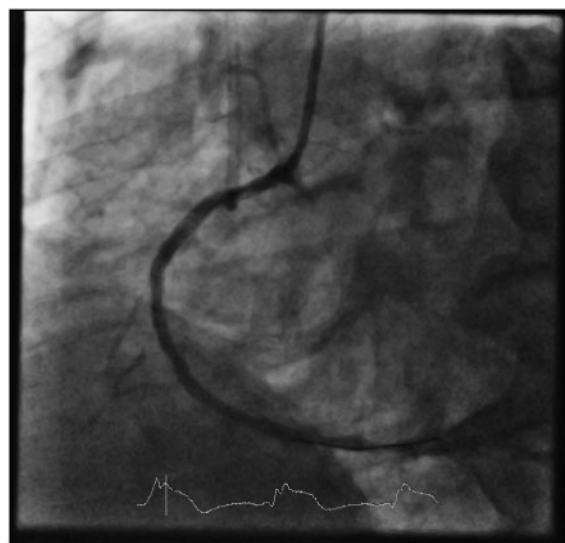
Our patient reported compliance with his medications but added that he had seen tablets 'passing whole' into his colostomy bag, 2–3 h after ingestion. To overcome this problem, and after discussion with pharmacologists, his antiplatelet tablets were crushed prior to ingestion. The patient remained well 12 months following the event.

## Discussion

Drug absorption from the gastrointestinal tract is altered when significant lengths of the gut are resected. There is correlation between drug absorption and the length of the remaining small intestine.<sup>9</sup> Altered intestinal luminal transit time and the lack of sufficient contact time with intestinal mucosa in patients with short-bowel may lead to reduced bioavailability of drugs. There is minimal literature in this area and problems of antiplatelet drug absorption can easily be overlooked in day-to-day practice, resulting in-stent thrombosis. The



**Figure 1** Thrombotic ostial occlusion demonstrated in the right coronary artery with TIMI 0 flow.



**Figure 2** Right coronary artery, with TIMI III flow, after balloon dilatation and stenting.

aetiology of stent thrombosis can be ascertained using intravascular imaging techniques such as OCT or IVUS.

Patients with short-bowel lengths or malabsorption syndromes should be treated with caution, and consideration should be given to the use of platelet function testing post-stenting. In the presence of inadequate platelet inhibition, different formulations or doses of antiplatelet therapy can be trailed, and response to therapy should be

monitored. In such cases, we suggest discussion with a pharmacist or medicines information service. In addition, it may be appropriate to enlist the support of an experienced gastroenterologist, preferably in the multidisciplinary environment of an intestinal rehabilitation centre.<sup>10</sup>

## Lead author biography



Dr. Atifur Rahman is an interventional cardiologist and the clinical director of the coronary care unit at Gold Coast University Hospital. He is an Associate Professor at Griffith University School of Medicine and Associate professor at BOND University Faculty of health science & medicine. He is a Regional Examiner for the Royal Australasian College of Physicians.

## Supplementary material

Supplementary material is available at *European Heart Journal - Case Reports* online.

**Slide sets:** A fully edited slide set detailing this case and suitable for local presentation is available online as [Supplementary data](#).

**Consent:** The author/s confirm that written consent for submission and publication of this case report including image(s) and associated text has been obtained from the patient in line with COPE guidance.

**Conflict of interest:** none declared.

## References

1. Byrne R, Joner M, Kastrati A. Stent thrombosis and restenosis: what have we learned and where are we going? The Andreas Gruntzig lecture ESC 2014. *Eur Heart J* 2015;**36**:3320–3331.
2. Cassese S, Byrne RA, Tada T, Piniček S, Joner M, Ibrahim T, King LA, Fusaro M, Laugwitz K-L, Kastrati A. Incidence and predictors of restenosis after coronary stenting in 10 004 patients with surveillance angiography. *Heart* 2014;**100**: 153–159.
3. Raugaard B, Jensen LO, Tilsted HH, Christiansen EH, Maeng M, Terkelsen CJ, Krusell LR, Kaltoft A, Kristensen SD, Bøtker HE, Thuesen L, Aarøe J, Jensen SE, Villadsen AB, Thayssen P, Veien KT, Hansen KN, Junker A, Madsen M, Ravkilde J, Lassen JF; Scandinavian Organization for Randomized Trials with Clinical Outcome (SORT OUT). Zotarolimus-eluting durable-polymer-coated stent versus a biolimus-eluting biodegradable-polymer-coated stent in unselected patients undergoing percutaneous coronary intervention (SORT OUT VI): a randomised non-inferiority trial. *Lancet* 2015;**385**:1527–1535.
4. van Werkum J, Godschalk T, Oirbans T, ten Berg J. Coronary stent thrombosis: incidence, predictors and triggering mechanisms. *Intervent Cardiol* 2011;**3**: 581–588.
5. Kimura T, Morimoto T, Kozuma K, Honda Y, Kume T, Aizawa T, Mitsudo K, Miyazaki S, Yamaguchi T, Hiyoshi E, Nishimura E, Isshiki T. Comparisons of baseline demographics, clinical presentation, and long-term outcome among patients with early, late, and very late stent thrombosis of sirolimus-eluting stents: observations from the Registry of Stent Thrombosis for Review and Reevaluation (RESTART). *Circulation* 2010;**122**:52–61.

6. Van Werkum JW, Heestermaans AA, Zomer AC, Kelder JC, Suttorp MJ, Rensing BJ, Koolen JJ, Brueren BR, Dambrink JH, Hautvast RW, Verheugt FW, ten Berg JM. Predictors of coronary stent thrombosis: the Dutch Stent Thrombosis Registry. *J Am Coll Cardiol* 2009;**53**:1399–1409.
7. Tada T, Byrne RA, Simunovic I, King LA, Cassese S, Joner M, Fusaro M, Schneider S, Schulz S, Ibrahim T, Ott I, Massberg S, Laugwitz K-L, Kastrati A. Risk of stent thrombosis among bare-metal stents, first-generation drug-eluting stents, and second-generation drug-eluting stents: results from a registry of 18,334 patients. *JACC Cardiovasc Interv* 2013;**6**:1267–1274.
8. Iakovou I, Schmidt T, Bonizzi E, Ge L, Sangiorgi GM, Stankovic G, Airoldi F, Chieffo A, Montorfano M, Carlino M, Michev I, Corvaja N, Briguori C, Gerckens U, Grube E, Colombo A. Incidence, predictors, and outcome of thrombosis after successful implantation of drug-eluting stents. *JAMA* 2005;**293**:2126–2130.
9. Menardi G, Guggenbichler JP. Bioavailability of oral antibiotics in children with short-bowel syndrome. *J Pediatr Surg* 1984;**19**:84–86.
10. Sood S, Tanner F, Testro A. Prescribing for a patient with reduced intestinal length. *Aust Prescr* 2013;**36**:136–181.