

Epidermal Growth Factor Restores Cytokeratin Expression in Rats with Diabetes

Author

Al-Ankily, Mahmoud M., Shamel, Mohamed, Bakr, Mahmoud

Published

2018

Journal Title

Journal of Research in Medical and Dental Science

Version

Version of Record (VoR)

Rights statement

© 2018 Mahmoud M Bakr. This is an Open Access article distributed under the terms of the Creative Commons Attribution-NonCommercial-NoDerivs 4.0 International (CC BY-NC-ND 4.0) License (<http://creativecommons.org/licenses/by-nc-nd/4.0/>) which permits unrestricted, non-commercial use, distribution and reproduction in any medium, providing that the work is properly cited.

Downloaded from

<http://hdl.handle.net/10072/371958>

Link to published version

<https://jrmds.in/index.php/JRMDS/article/view/416>

Griffith Research Online

<https://research-repository.griffith.edu.au>



Epidermal Growth Factor Restores Cytokeratin Expression in Rats with Diabetes

Mahmoud M Al-Ankily¹, Mohamed Shamel², Mahmoud M Bakr^{3*}

¹Lecturer, Oral Biology Department, Faculty of Dentistry, the British University in Egypt, Cairo, Egypt

²Lecturer, Oral Biology Department, Faculty of Dentistry, Modern Sciences and Arts University, Cairo, Egypt

³Lecturer in General Dental Practice, School of Dentistry and Oral Health, Griffith University, Queensland, 4222, Australia

DOI: 10.24896/jrmds.20186132

ABSTRACT

Diabetes Mellitus (DM) has been associated with salivary glands dysfunction and disorders. Epidermal Growth Factor (EGF) is highly important in the process of wound healing in different parts of the body. The aim of the present study is to investigate the capacity of EGF to reverse the side effects of Streptozotocin (STZ) induced diabetes in the submandibular salivary glands of adult Albino male rats, through immunohistochemical localization of cytokeratin in the parenchyma of the glands. Sixty rats were used in this study and were divided into three equal groups, a control group, an STZ induced group and EGF group where STZ induced rats are treated with a daily EGF injection of a dose of 10 µg/Kg body weight for two months. The overall expression of cytokeratin in the submandibular salivary glands of STZ induced rats decreased significantly when compared to the control group. However, in EGF group, cytokeratin expression levels were restored to values that were nearly equal to normal levels. Daily intraperitoneal injection of epidermal growth factor in a dose of 10 µg/Kg body weight for two months, helped reverse the negative side effects of DM in STZ induced rats. However, a small amount of permanent damage was still evident. Future research will be conducted to confirm the above findings through immunohistochemical expression of myosin and E-cadherin as well as ultrastructural examination.

Keywords: Submandibular Salivary Gland, Epidermal Growth Factor, Diabetes, Streptozotocin, Cytokeratin

HOW TO CITE THIS ARTICLE: Mahmoud M Al-Ankily, Mohamed Shamel, Mahmoud M Bakr, Epidermal Growth Factor Restores Cytokeratin Expression in Rats with Diabetes, J Res Med Dent Sci, 2018, 6 (1): 196-203, DOI: 10.24896/jrmds.20186132

Corresponding author: Dr. Mahmoud Bakr

e-mail ✉ m.bakr@griffith.edu.au

Received: 15/09/2017

Accepted: 10/10/2017

retinopathy, cardiomyopathy, microangiopathy, atherosclerosis, and foot ulcers [2].

INTRODUCTION

Diabetes mellitus (DM) is one of the oldest conditions characterized in humans, having been recognized since antiquity. It is a major health problem at present. Diabetes was one of the first diseases described with an Egyptian manuscript from c. 1500 BCE mentioning "too great emptying of the urine" [1]. This in turn results in an increase in blood glucose concentration (hyperglycemia) that ultimately leads to several acute and chronic complications including neuropathy, nephropathy,

Diabetes mellitus consists of type 1 (insulin-dependent) and type 2 (non-insulin-dependent) varieties. Type 1, previously called juvenile-onset diabetes, is induced by damage to the insulin-producing cells and is usually diagnosed in children and young adults, while type 2, previously called adult-onset diabetes, accounts for about 90% to 95% of all diagnosed cases of diabetes and is associated with older age, obesity, family history of diabetes, impaired glucose metabolism, and race/ethnicity [3].

Saliva and salivary glands are considered the strongest link between oral and systemic health. Saliva is a fluid lubricates food to assist deglutition, moistens the buccal mucosa that is important for speech, provides an aqueous solvent necessary for taste and also secretes antimicrobial agents as IgA, lysozymes and Lactoferrin [4]. Saliva contributes significantly to the protective barrier of oral epithelium through its mechanical rinsing action and the unique peptides it contains. Saliva contains several types of antimicrobial peptides, including defensins, which may have an important role in innate host defense [5]. The submandibular salivary gland is one of the major salivary glands that were considered as a scope to be studied under the effect of diabetes mellitus. It is a compound tubulo-alveolar exocrine gland that produces 60% of the salivary output [6].

Epidermal growth factor (EGF) is a potent growth factor that plays an important role in promoting the process of wound healing through stimulating proliferation and migration of fibroblasts [7]. EGF is a pivotal factor in the healing cascade, acting on epithelial cells and fibroblasts and thereby promoting the restoration of damaged epithelium [8]. Salivary derived growth factors, including epidermal growth factor (EGF), are thought to play a role in helping maintain levels of oral health, promoting wound healing, and maintaining mucosal integrity [9].

From the available literature, the relationship between diabetes mellitus and the salivary gland dysfunctions was previously studied. Many reports have been performed on the therapeutic effect of epidermal growth factor on wound healing of skin, mucosa and other vital organs subjected to diabetes [10], while the effect of this important factor on submandibular salivary gland was not previously examined. Therefore our study aimed to explore the impact of epidermal growth factor on the structural integrity of submandibular salivary glands of streptozotocin induced male albino rats.

Aim of the study

The aim of the present investigation is to find out whether epidermal growth factor can alleviate the well documented side effects of streptozotocin induced diabetes mellitus on the submandibular salivary gland of adult male Albino rats or not, through Immunohistochemical localization of the cytokeratin in the parenchyma of the gland.

MATERIALS AND METHODS

This project was reviewed and granted ethical approval by the Suez Canal University Research Ethics Committee (SUEZ-REC 23/2014).

Sixty adult male Albino rats, three months old with an average weight of 220 gm were used in this study. Rats were obtained from Kasr el Aini animal experimental unit, Faculty of Medicine, Cairo University. The rats were housed in separate cages, five rats per cage and kept in an environment with controlled temperature (25°C), humidity (45%-75%), and photoperiod (12:12 hour light-dark cycle). The animals were fed natural diet and supplied drinking water ad libitum throughout the whole experimental period. The rats were acclimatized for one week before the initiation of the experiment.

The animals were divided into three groups as follows:

- Control group: consisted of 20 rats, and served as controls.
- Diabetes group: consisted of 20 rats and subjected to induction of diabetes mellitus using streptozotocin STZ (Sigma-Aldrich Co).
- Diabetes + Epidermal growth factor (EGF): consisted of 20 rats those were treated with streptozotocin as the diabetes group animals. After verifying their condition of diabetes, they were subjected to a single daily intraperitoneal injection of epidermal growth factor (Epidermal Growth Factor, human -animal component free-recombinant, expressed in *E. coli*) provided by Sigma-Aldrich, Inc. in a dose of 10 µg/Kg body weight for two months.

Diabetes was induced using a single intraperitoneal injection of freshly prepared streptozotocin dissolved in 0.1 M sodium citrate buffer [11]. Rats were subjected to a 16 hour fasting period before the STZ injection. To verify induction of diabetes mellitus, blood samples were collected from the retro orbital plexus of veins at the inner canthus of the eye of the animals of each group to detect the blood sugar level. Animals were not included in the experiment unless they demonstrated serum glucose level greater than 250 mg/dl. Blood glucose level of the rats was monitored by periodic examination of blood samples every week, using Glucochek SC. At the end of the experiment, rats of all groups were euthanized, and their submandibular salivary glands were dissected.

Submandibular salivary glands were processed for histological examination and stained with Immuno-peroxidase staining for immunohistochemical localization of cytokeratin in the glandular tissue using staining reaction incubated by Anticytokeratin (CK number 5, 6 and 18 Antibody). For cytokeratin immunohistochemical localization, negative controls were prepared by substituting the primary antibody by a nonspecific serum of the same dilution as its respective antibody and the procedures were continued as usual. Five sections from each submandibular salivary glands stained with anticytokeratin antibody were selected, examined with ZEISS Primo Star light microscopy and photographed by Tucsen IS 1000 10.0MP Camera in the Oral Biology lab, Faculty of Dentistry, British University in Egypt.

The staining reaction of the different immunohistochemical parameters of the different groups was scored as follows:

- (-) negative staining reactivity
- (+) weakly positive staining reactivity
- (++) moderately positive staining reactivity
- (+++ strongly positive staining reactivity

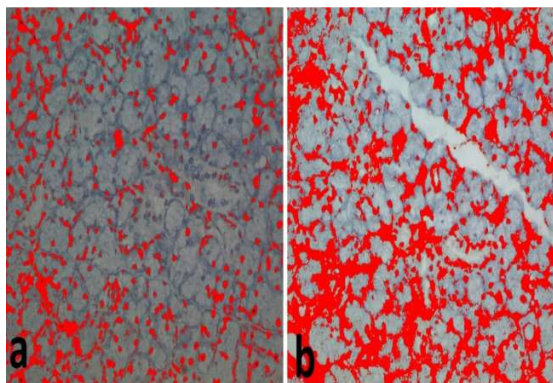


Figure 1: Showing examples of images where cytokeratin expression was masked by red color and the grey background was considered negative (a): Control Group, (b): EGF group.

The intensity of the immunohistochemical staining results from different groups were histometrically analyzed using Image J (1.46 a, NIH, USA) computer system (1.46 a, NIH, USA). For each selected section, six microscopic fields were selected and captured at a magnification 200X using a digital video camera mounted on a light microscope (CX21, Olympus, Japan). Images were then transferred to the computer system for

analysis. Images were manually corrected for brightness and contrast. Colour thresholding was then performed automatically after which pictures were converted to RGB stack type. Masking of the brown cytokeratin, immuno-stain was performed by red colour where any brown stain of any intensity was considered positive whereas the background grey stain was considered negative (Fig 1). Area fraction was then calculated automatically representing the area percentage of immune positive cells to the total area of the microscopic field.

All data obtained from histomorphometric analysis was statistically described in terms of range, mean, standard deviation (SD), and median. Comparison between groups was done using Kruskal Wallis analysis of variance (ANOVA) test with Conover-Inman test for independent samples as post hoc multiple 2-group comparisons. A p value less than 0.05 was considered statistically significant. All statistical analysis was done using Microsoft Excel 2013 (Microsoft Corporation, NY, USA) and Statistical Package for the Social Sciences version 21 (SPSS Inc., Chicago, IL).

RESULTS

Negative control

Sections were taken from the submandibular salivary glands of rats from the control group and incubated with non-specific serum and colour developed by DAB revealed negative staining reaction of all the elements forming the gland.

Control group

The serous secretory cells showed a moderately positive staining reaction of the cytoplasm. While mucous secretory cells represented either negative or weakly positive staining pattern. All duct system including the intercalated ducts, striated ducts, granular convoluted tubules, and excretory ducts revealed strongly positive staining reaction. The pattern of the staining represented as diffuse cytoplasmic staining; as in intercalated, striated and excretory ducts. While the granular convoluted tubules showed two patterns of staining, either diffuse or limited to the granular components. Moderately to strongly positive reaction was found in the connective tissue cells and walls of blood vessels (Fig 2).

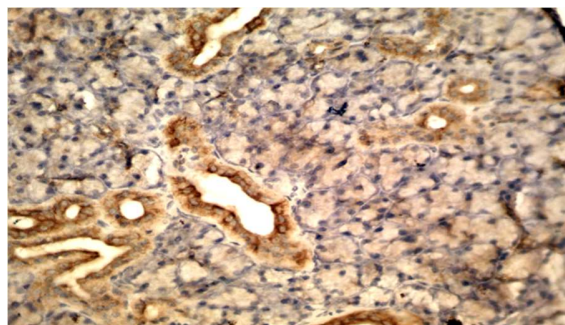


Figure 2: A photomicrograph of a Submandibular salivary gland from the control group incubated with non-specific serum and color developed by DAB showing negative staining reaction of the entire gland component. (Original magnification x 200)

Diabetes group

There was an overall decrease in the staining intensity of all the glandular elements. The serous secretory cells showed a weakly positive cytoplasmic staining reaction in most of the cases. The mucous secretory cells demonstrated a negative staining reaction. The ductal cells in all duct system showed fainter staining reaction compared with control group. The intercalated ducts, striated ducts, granular convoluted tubules, and excretory ducts revealed weakly to moderately positive staining pattern. The connective tissue cells and walls of blood vessels showed weakly to moderately positive staining reaction (Fig. 3).

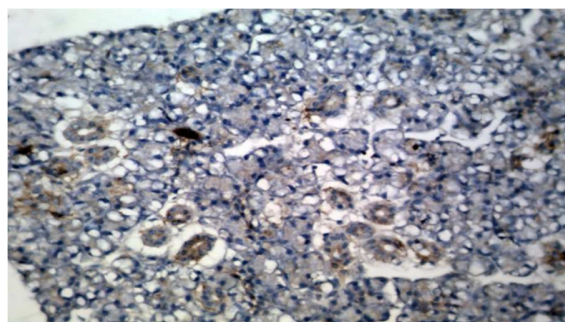


Figure 3: A photomicrograph of a Submandibular salivary gland from the diabetes group incubated with anticytokeratin monoclonal antibody CK # 5, 6 and 18 and color developed by DAB showing weakly positive reaction of serous acinar cells, and weakly to moderately positive reaction in the ductal cells. (Original magnification x 200)

Diabetes + Epidermal Growth Factor (EGF) group

The serous secretory cells showed moderately positive staining reaction of their cytoplasm. While mucous secretory cells represented

negative staining pattern. All duct system including the intercalated ducts, striated ducts, granular convoluted tubules, and excretory ducts revealed moderately to strongly positive staining reaction. The pattern of the staining represented as diffuse cytoplasmic staining; as in intercalated, striated and excretory ducts. While the granular convoluted tubules showed two patterns of staining, either diffuse or limited to the granular parts. Moderately to strongly positive reaction was found in the connective tissue cells and walls of blood vessels (Fig 4). The scores for staining reactions and immunohistochemical expression of cytokeratin in different components of the submandibular salivary glands in all groups are summarized in table 1.

Table 1: Illustrates the scores of staining intensity of the submandibular salivary glands to C=cytokeratin

Group	Control	Diabetes	EGF
Serous cells	++	+	++
Mucous cells	-/+	-	-
Myoepithelial cells	+	+	+
Intercalated ducts	+++	+ / ++	++ / +++
Striated cells	+++	+ / ++	++ / +++
Granular convoluted tubules	+++	+ / ++	++ / +++
Excretory ducts	+++	+ / ++	++ / +++
Connective tissue cells	++ / +++	+	++ / +++
Wall of blood vessels	++ / +++	+ / ++	++ / +++

- Negative staining reactivity
 + Weakly positive staining reactivity
 ++ Moderately positive staining reactivity
 +++ Strongly positive staining reactivity

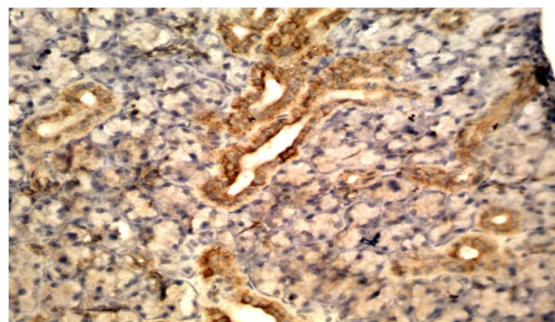


Figure 4: A photomicrograph of a Submandibular salivary gland from the rats with diabetes after treatment with EGF and incubated with anticytokeratin monoclonal antibody CK # 5, 6 and 18 and color developed by DAB showing moderately positive reaction of serous acinar cells, and moderately to strongly positive reaction in the ductal cells. (Original magnification x 200)

Statistical Results

Histomorphometric analysis of the submandibular salivary gland of the three groups revealed that the highest mean area percent occupied by

cytokeratin immunostaining was recorded in the control group, whereas the lowest value was recorded in the Diabetes group. Statistical analysis of variance (ANOVA test), revealed that the difference in the mean area percentage of expression of Cytokeratin immunostaining was extremely statistically significant ($p < 0.0001$).

A pairwise comparison was held between cytokeratin mean area expression percentage in control group and the other experimental groups using an unpaired (independent) Student's t-test. There was a statistically significant decrease in the cytokeratin expression area percentage in the diabetes group than the control group ($p < 0.0001$). While when comparing groups the control and EGF groups, there was a statistically significant decrease in the cytokeratin expression area percentage in the EGF group than the control group ($p < 0.05$). Finally, comparing cytokeratin expression area percentage between diabetes group and the EGF group, there was an extremely significant increase in cytokeratin expression area percentage in the EGF group ($p < 0.0001$).

DISCUSSION

In the present study, salivary glands were the organ of choice for studying the link between oral and systematic health. The submandibular salivary gland (SMG) is one of the major salivary gland. It produces about 60% of salivary output. As rats' submandibular Salivary gland is structurally and functionally almost similar to human salivary gland, their use as models in this study may be applicable to human salivary glands in physiology and disease.

The aim of this study was to detect the immunohistochemical localization of the cytokeratin in the parenchyma of the gland. Various studies have demonstrated the labelling of epithelial cytoskeletal proteins of the salivary gland with the anticytokeratins [12-15]. Cytokeratins (CK) are intermediate filaments mostly expressed by epithelial cells, which includes a wide range of proteins, varying in molecular weight, isoelectric pH values, and affinity [16]. CK expression varies among different types of epithelia in their different stages of development, and they may be used as an adjunctive tool for epithelial classification and histological diagnosis [17].

Any pathological condition or deviation from normal may affect the distribution of the specific cellular molecular markers including CK. The immunohistochemical methods used in detection of cytokeratin filaments was the immunoperoxidase method proved to be more rapid, highly sensitive and more elaborated than the ultrastructural detection of cytokeratin filaments which need to be aggregated in bundles to be identified by the electron microscope [18].

Combined use of various monoclonal antibodies (mAbs) may provide useful probe in the detection of cytokeratin antibodies in all the epithelial structures of the salivary gland. In the present study monoclonal antibodies of clone LP34 were used to react with specific cytokeratin polypeptide number 5, 6 and 18. In the control group most of the serous acinar cells as well as ductal cells gave moderately to strongly positive staining reaction to anticytokeratin. This is in accordance with a study that found that the acinar cells showed a positive reaction with mAbs specific for CKs of simple epithelia (CK8 & CK18), as well as those CKs specific for epithelial cells of intercalated, striated and excretory duct of rat Submandibular Salivary Glands (CK 7, 8, and 18) [13]. It is also in agreement with another study which stated that the normal salivary glands showed immunoperoxidase expression according to each individual structure. In serous acini CK 6 and 19 were eventually expressed. Intercalated ducts were mainly positive for CK 6, 7, 18, and 19 and striated ducts for CK 6, 7, 8, 13, 18, and 19. In excretory ducts luminal cells were mainly immunopositive for CK 6, 7, 8, 18, and 19, and basal cells for CK14 [12].

The moderate staining reaction of the acinar cells compared to strong reaction revealed by the duct cells can be related to the sequence of cyto-differentiation of the ductal cells before the terminal branches, as the acinar cells is the last to develop with less cytokeratin formation. This is in agreement with a number of studies in the literature on human salivary glands [19-21] as well as on rats' salivary glands [22].

The negative or weak staining pattern of mucous secretory cells found in this study coincides with another study that stated the reaction in serous cells was more distinct than that in mucous cells [13]. This could be explained due to the weak staining of mucous acinar cells as a consequence of the mucin present. Another study found that the

positive cytokeratin reaction was diffuse in the epithelial structures of the normal salivary glands, more intensely spread in the ductal luminal cells and less intense in the basal ductal cells [14]. The moderate positive staining reaction of the connective tissue with anticytokeratin antibodies is due to the staining of macrophages engulfing epithelial cells containing cytokeratin polypeptides, and the positive staining of the wall of blood vessels reported in the present investigation is due to endothelial lining with its content of cytokeratin polypeptides [23].

On the other hand, examination of the submandibular salivary gland of rats with diabetes, distorted glandular elements represented a generalized decrease in their staining reactivity to cytokeratin. The decrease of cytokeratin staining reactivity in the submandibular salivary gland of rats with diabetes compared to the control group, denotes a decrease in the cytoplasmic content of cytokeratins, which play a major role in cell to cell contact, cell matrix content, anchor the nucleus within the cell and form the structure of vital cell organelles as the Golgi apparatus [24]. Therefore, they are important constituent of epithelial cells, responsible for keeping the epithelial cellular junctions, maintaining their tensile strength and their structural integrity. Any disturbance to cytokeratins, led to deformity of acinar cells, defective cellular junctions, as tonofilaments share in the formation of desmosomal junctions, leading to wide intercellular junctions, distorted Golgi complex, thus hindering the final outcome of the secretory products from condensation, adding glycogen and the final packing of the secretory products, resulting in reduction of granular content, reduction of electron density together with loss of their characteristic form [25].

Immunohistochemically myoepithelial cells are found to contain keratin intermediate filaments and are, therefore, considered to have an epithelial origin but at the same time they contain a large number of myofilaments which represent a massive expression of contractile proteins such as actin and myosin. The contractile protein myosin serves as intracellular muscles and is concerned with maintenance of cell shape, cytoplasmic movement and cell contractility [26]. The myoepithelial cells are present in many exocrine glands, such as the salivary glands, sweat glands and mammary glands, suggesting a role in the

transport function, contractile mechanism and mitotic cell division [27].

CONCLUSIONS

Daily intraperitoneal injection of epidermal growth factor in a dose of 10 µg/Kg body weight for two months resulted in improvement of the submandibular salivary glands parenchymal and stromal elements. This was confirmed by immunohistochemical localization of cytokeratin.

Recommendations and future research

The overall experience with EGF is very promising. However, several issues need to be further clarified before recommending use of EGF in everyday practice. These include optimal dosage, route of administration, and cost-effectiveness. Further research is being conducted by our team to investigate the effect of EGF on the submandibular salivary glands in STZ induced rats through localization of myosin and E-cadherin. The finding obtained from all immunohistochemical markers will be confirmed both histologically and ultrastructurally.

Acknowledgement

This project was reviewed and granted ethical approval by the Suez Canal University Research Ethics Committee (SUEZ-REC 23/2014).

Conflicts of interest

None declared.

REFERENCES

1. Leutholtz BC, Ripoll I. Exercise and disease management. 2nd ed. Boca Raton: CRC Press, 2011: 25.
2. Williams JC, Pickup G. Complications of diabetes mellitus. In Handbook of Diabetes. Blackwell Science. Livingston: Cambridge University Press, 1998: 14-18.
3. Hasegawa H, Ozawa S, Hashimoto K, Takeichi T, Ogawa T. Type 2 diabetes impairs implant osseointegration capacity in rats. International Journal of Oral & Maxillofacial Implants. 2008; 23(2): 237-46.
4. Dodds MW, Johnson DA, Yeh CK. Health benefits of saliva: a review. Journal of Dentistry. 2005; 33(3):223-33.
5. Abiko Y, Saitoh M. Salivary defensins and their importance in oral health and disease. Current

- Pharmaceutical Design. 2007; 13(30):3065-72.
6. EL-Gusbi GAM, Shredah MTH, Soliman AE. Submandibular Glands as an Evident of the Effects of Antioxidant on Alloxan-Induced Diabetic Rats. *World J Med Sci* 2014; 11(2): 210-16.
 7. Kwon YB, Kim HW, Roh DH, Yoon SY, Baek RM, Kim JY, Kweon H, Lee KG, Park YH, Lee JH. Topical application of epidermal growth factor accelerates wound healing by myofibroblast proliferation and collagen synthesis in rat. *Journal of Veterinary Science*. 2006; 7(2):105-09.
 8. Tiaka EK, Papanas N, Manolakis AC, Georgiadis GS. Epidermal growth factor in the treatment of diabetic foot ulcers: an update. *Perspectives in Vascular Surgery and Endovascular Therapy*. 2012; 24(1):37-44.
 9. Oxford GE, Tayari L, Barfoot MD, Peck AB, Tanaka Y, Humphreys-Beher MG. Salivary EGF levels reduced in diabetic patients. *Journal of Diabetes and its Complications*. 2000; 14(3):140-45.
 10. Al-Ankily MM, Shamel M, Bakr MM. Epidermal growth factor and diabetes mellitus; friends or faux?. *International Journal of Medical and Dental Sciences*. 2016; 5(2):1290-96.
 11. Fahim MA, Hasan MY, Alshuaib WB. Cadmium modulates diabetes-induced alterations in murine neuromuscular junction. *Endocrine Research*. 2000; 26(2):205-17.
 12. Azevedo RS, de Almeida OP, Kowalski LP, Pires FR. Comparative cytokeratin expression in the different cell types of salivary gland mucoepidermoid carcinoma. *Head and Neck Pathology*. 2008; 2(4):257-64.
 13. Dozic I, Todorovic T, Dozic B, Colic M. Immunohistochemical identification of cytokeratins in the rat submandibular salivary glands during ontogenesis. *Acta veterinaria* 2009; 59(1): 69-80.
 14. Dăguci LU, Stepan A, Merçuț VE, Dăguci C, Bătăiosu M, Florescu A. Immunohistochemical expression of CK7, CK5/6, CK19, and p63 in Warthin tumor. *Rom J Morphol Embryol*. 2012; 53(3):603-07.
 15. Schwarz S, Zenk J, Muller M, Ettl T, Wunsch PH, Hartmann A, Agaimy A. The many faces of acinic cell carcinomas of the salivary glands: a study of 40 cases relating histological and immunohistological subtypes to clinical parameters and prognosis. *Histopathology*. 2012; 61(3): 395-408.
 16. Kirfel J, Magin TM, Reichelt J. Keratins: a structural scaffold with emerging functions. *Cellular and Molecular Life Sciences CMLS*. 2003; 60(1):56-71.
 17. Chu PG, Weiss LM. Keratin expression in human tissues and neoplasms. *Histopathology*. 2002; 40(5): 403-39.
 18. Schlegel R, Banks-Schlegel S, Pinkus GS. Immunohistochemical localization of keratin in normal human tissues. *Laboratory Investigation; a Journal of Technical Methods and Pathology*. 1980; 42(1):91-96.
 19. Kusama K, Jiang Y, Ohno J, Shikata H, Ishikawa F, Taguchi K, Kikuchi K, Mori K, Sakashita H, Sakagami H, Kaneko T. Immunohistochemical detection of cytokeratin 18 and its neo-epitope in human salivary glands and pleomorphic adenomas. *Anticancer Research*. 2000; 20(4):2485-87.
 20. Fukuda M, Tanaka A, Kitada M, Fukuda F, Suzuki S, Jiang Y, Kebusa Y, Ohno J, Yamamoto Y, Minato H, Nonomura A, Sakashita H, Kusama K. Immunohistochemical detection of cytokeratin 18 and its neo-epitope in Warthins tumor (adenolymphoma) of the parotid glands. *Anticancer Research*. 2001; 21(1A): 109-12.
 21. Ogawa Y, Kishino M, Atsumi Y, Kimoto M, Fukuda Y, Ishida T, Ijuhin N. Plasmacytoid cells in salivary-gland pleomorphic adenomas: evidence of luminal cell differentiation. *Virchows Archiv*. 2003; 443(5):625-34.
 22. Takahashi S, Wakita M. Cytokeratin expression during regeneration of the intralobular duct in rat submandibular glands after YAG laser irradiation. *Archives of Histology and Cytology*. 1994; 57(2): 167-73.
 23. Fouad BG, Ghali LS, Ali MM. Ultrastructural and immunohistochemical investigation on the effect of certain commonly used diuretics on the submandibular salivary glands of the rats, with special reference to the incidence of dental caries. PhD Thesis. Suez Canal University, 2005.
 24. Hidayat M, Tahir M, Shoro AA. Melatonin preserves the morphology of parotid gland damaged by streptozotocin induced diabetes. *Journal of Postgraduate Medical Institute (Peshawar-Pakistan)*. 2014; 28(2): 128-32.
 25. Hashimoto J, Yamada K, Ogata K, Takai Y, Mori M. Immunoreaction of keratin, actin, S-100 protein and rat-EGF in ductligated rat salivary glands. *Journal of Oral Pathology & Medicine*. 1992; 21(5):214-20.

26. Chitturi RT, Veeravarmal V, Nirmal RM, Reddy BV. Myoepithelial cells (MEC) of the salivary glands in health and tumours. *Journal of Clinical and Diagnostic Research: JCDR*. 2015; 9(3):ZE14-ZE18.
27. Redman RS. Myoepithelium of salivary glands. *Microscopy Research and Technique*. 1994; 27(1):25-45.