

**PSMA-PET detected port site recurrence of prostate cancer following minimally invasive radical prostatectomy and utilisation of hookwire localisation for excision**

Author

Harrison, W, Nesbitt, A, Sillar, D

Published

2023

Journal Title

Urology Case Reports

Version

Version of Record (VoR)

DOI

[10.1016/j.eucr.2023.102570](https://doi.org/10.1016/j.eucr.2023.102570)

Rights statement


© 2023 Published by Elsevier Inc. This is an open access article under the CC BY-NC-ND license (<http://creativecommons.org/licenses/by-nc-nd/4.0/>).

Downloaded from

<http://hdl.handle.net/10072/426607>

Griffith Research Online

<https://research-repository.griffith.edu.au>



## Oncology

# PSMA-PET detected port site recurrence of prostate cancer following minimally invasive radical prostatectomy and utilisation of hookwire localisation for excision

William Harrison<sup>\*,1</sup>, Alexander Nesbitt, David Sillar

NSW Health, The Tweed Hospital, 16 Powell St, Tweed Heads, NSW, 2560, Australia

## ARTICLE INFO

## Keywords:

PSMA-PET  
Prostate cancer  
Biochemical recurrence  
Minimally invasive radical prostatectomy  
Port site metastases  
Image-guided techniques

## ABSTRACT

Biochemical recurrence following prostate cancer treatment is well-known, with predictable sites typically observed in the prostate bed, lymph nodes, or skeleton. The emergence of PSMA-PET scans has revealed the potential for early recurrence in non-conventional sites, including port site metastases. Our report presents a rare case of abdominal wall metastasis detected 97 months post-prostatectomy. The excision of this subcutaneous lesion using image-guided hookwire techniques showed promise in minimising morbidity while providing successful oncologic outcomes. Further investigation is needed to establish the efficacy of PSMA-PET-guided interventions on long-term patient outcomes in treating prostate cancer port site metastases.

## 1. Introduction

Biochemical recurrence of prostate cancer is a relatively common phenomenon following curative intent radical prostatectomy, with sites of recurrence typically predictable in the prostate bed, lymph nodes, or skeleton. While it has traditionally been managed through early or delayed androgen deprivation therapy, the emergence of more sensitive imaging techniques, such as prostate-specific membrane antigen-positron emission tomography (PSMA-PET), has revealed the potential for early recurrence to manifest outside of these conventional sites.<sup>1</sup>

Although port site metastases after minimally invasive radical prostatectomy have been previously described, they remain exceptionally rare, with only 13 documented cases in the published English literature.<sup>2,3</sup> Herein, we present a novel technique for excising a prostate cancer port site abdominal wall metastasis, employing image-guided hook wire techniques utilized in other oncological surgeries.

## 2. Case presentation

A 61-year-old man underwent laparoscopic radical prostatectomy due to organ-confined prostate cancer detected during investigation for an elevated prostate-specific antigen (PSA) level of 7.6 µg/L. The procedure was completed without complications, and the specimen was

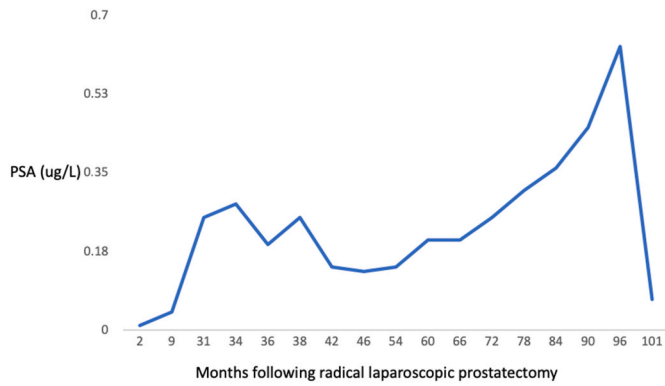
removed through the camera port using a laparoscopic specimen retrieval bag. Histology revealed pT3bN0 prostate adenocarcinoma with a Gleason score of 4 + 3 = 7 and positive surgical margins at the base of the prostate. Following the surgery, his first post-operative PSA level was 0.01 µg/L, and he opted for surveillance instead of adjuvant radiation therapy. Over the next three years, his PSA level slowly increased to 0.25 µg/L, and at that time, a PSMA-PET scan did not show any avidity.

PSA surveillance continued for the next four years, remaining relatively stable until the eighth year post-prostatectomy when the PSA level doubled within 18 months, reaching 0.63 µg/L (Fig. 1). A repeat PSMA-PET scan at this point revealed a right external iliac node metastasis, along with a small area of PSMA avidity in the subcutaneous abdominal fat (Fig. 2). An ultrasound examination displayed a small hypoechoic lesion measuring 3.6 mm in diameter in the region of interest. A fine needle aspiration was performed, confirming the presence of adenocarcinoma. Subsequently, the patient, now 70 years old, underwent salvage right-sided pelvic lymph node radiation therapy, administered at a dose of 64 Gy in 32 fractions. The urological team decided to excise the presumed subcutaneous metastasis, and a radiologist placed a pre-operative hook wire to aid in localisation, as the nodule was not palpable (Fig. 3). Under general anaesthesia, the lesion was successfully excised, and a margin of fat was taken around the nodule for

\* Corresponding author.

E-mail address: [wj.harrison89@gmail.com](mailto:wj.harrison89@gmail.com) (W. Harrison).

<sup>1</sup> Present address: Armstrong Clinic, Toowoomba Hospital, 16 Pechey Street, Toowoomba QLD 4350.



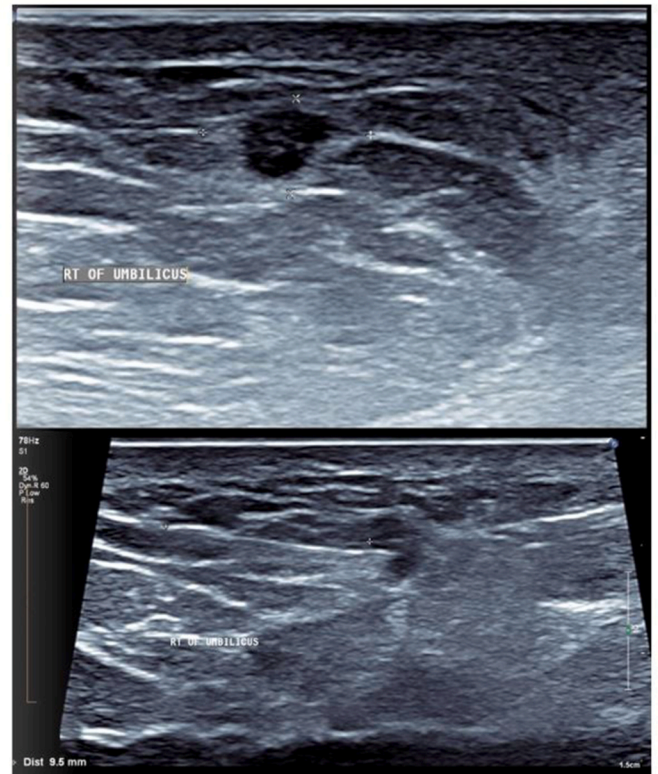
**Fig. 1.** Line graph depicting the changes in prostate-specific antigen (PSA) levels in micrograms per liter (ug/L) over time, measured in months following radical prostatectomy. The X-axis represents the months elapsed since the surgical procedure, while the Y-axis shows the corresponding PSA values.

examination. The histology confirmed a 4 mm nodule consisting of glands and complex cribriform structures consistent with metastatic prostate adenocarcinoma (Fig. 4).

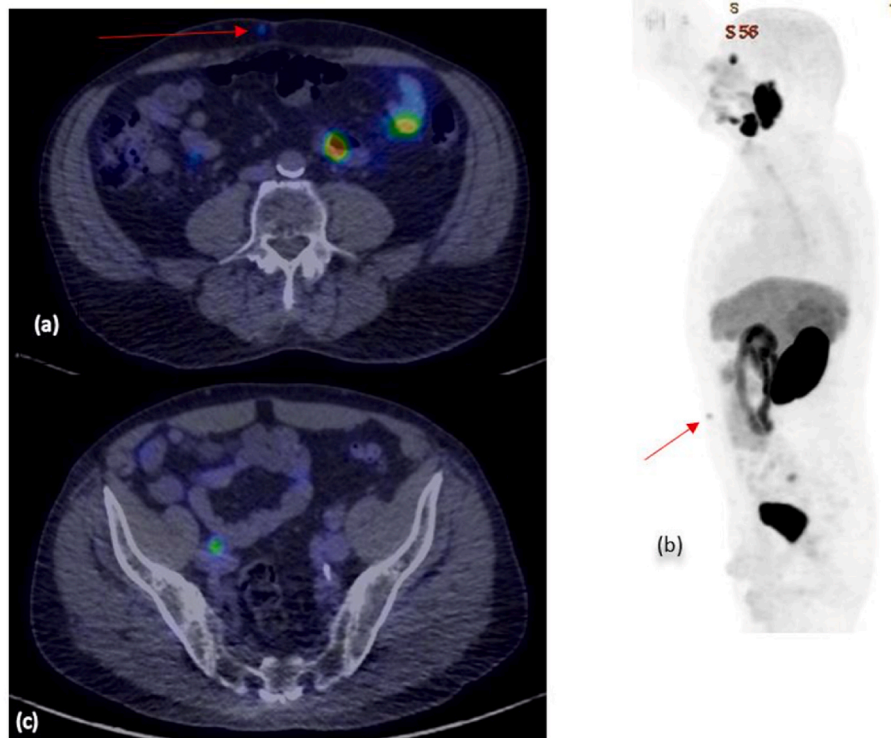
Two months following the completion of radiation therapy and excision of the subcutaneous metastasis, the patient’s PSA had fallen to 0.068 µg/L (Fig. 1).

**3. Discussion**

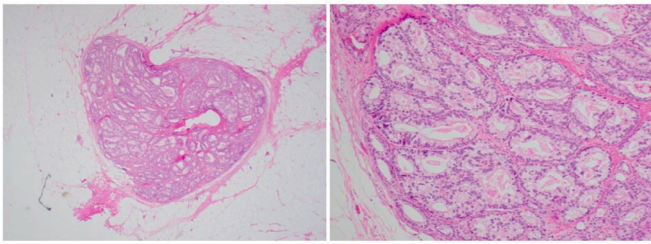
The introduction and rapid uptake of PSMA-PET scans over the last decade have significantly impacted the diagnosis of recurrent prostate cancer.<sup>4</sup> With the prevalence of robotic and laparoscopic techniques in most first-world countries for radical prostatectomies, it is reasonable to expect an increase in the detection of port site metastases as PSMA-PET



**Fig. 3.** Ultrasound-guided insertion of a hookwire into a small subcutaneous 3.6 mm anterior abdominal wall hypoechoic lesion. The superior image demonstrates the lesion, while the inferior image illustrates the accurate placement of the hookwire directly into the lesion of interest.



**Fig. 2.** PSMA-PET CT scan showing avidity in the anterior abdominal wall (indicated by the red arrow). The image on the left illustrates a fused axial scan, while the image on the right displays a whole-body sagittal projection. (For interpretation of the references to colour in this figure legend, the reader is referred to the Web version of this article.)



**Fig. 4.** Histopathological image of the excised lesion demonstrating glands and complex cribriform structures consistent with metastatic prostate adenocarcinoma.

scans become more widely utilized in the coming years. In a review of prostate cancer port site metastases, the median time between primary treatment and diagnosis of port site metastasis was 41.5 months. However, the case we are reporting on took 97 months between prostatectomy and the diagnosis of port site metastasis.

Various treatment modalities have been described after the detection of port site metastasis. Systemic treatment with standard androgen deprivation therapies, sometimes supplemented with docetaxel, has shown associations with biochemical response. Other innovative options, such as targeted cryotherapy and targeted radiation therapy, have also been described, with initial local responses unfortunately followed by biochemical or distant failure.<sup>2</sup> Surgical excision has been considered as a single modality treatment, but follow-up durations have not been sufficient to establish its efficacy.<sup>2</sup> The specific resection techniques have not been thoroughly described, although one reported case mentioned excision of metastases with wide margins, including en bloc resection of the external oblique muscle.<sup>5</sup>

While novel imaging techniques like PSMA-PET have shown promise in localising prostate cancer recurrence at an early stage, there is currently limited evidence regarding the long-term patient outcomes resulting from interventions based on these scans.<sup>4</sup> As with all surgical procedures, especially those involving novel techniques, it is essential for the surgeon to carefully weigh the risks of morbidity against the potential benefits of the intervention. In other clinical scenarios, the novel use of hook wire techniques in urological oncology during salvage pelvic lymph node dissection has been described as a means to reduce morbidity while achieving oncologic success.<sup>6</sup> In this article, we demonstrate the utility of this technique in minimising potential morbidity during diagnostic and potentially therapeutic excision of prostate cancer port site metastasis.

#### 4. Conclusion

PSMA-PET scans have revolutionised the diagnosis of recurrent prostate cancer, and their increasing utilisation may lead to more frequent detection of port site metastases and other non-conventional sites. This case report presents a rare instance of prostate cancer port site abdominal wall metastasis, detected 97 months after laparoscopic radical prostatectomy, along with the use of image-guided hook wire techniques for surgical excision.

Clinicians must weigh the risks and benefits of interventions, particularly when employing novel techniques. Although PSMA-PET scans enable early localisation of prostate cancer recurrence, their impact on long-term patient outcomes necessitates more comprehensive investigation. Future research with extended follow-up periods will facilitate a better understanding of the benefits and limitations of interventions based on these scans. Our case report significantly contributes to the growing knowledge of innovative approaches for diagnosing and treating prostate cancer port site metastases in the era of PSMA-PET.

#### Funding

This research did not receive any specific grant from funding agencies in the public, commercial, or not-for-profit sectors.

#### References

- Barbosa FG, Queiroz MA, Nunes RF, et al. Revisiting prostate cancer recurrence with PSMA PET: atlas of typical and atypical patterns of spread. *Radiographics*. 2019;39:186–212. <https://doi.org/10.1148/rg.2019180079>, 2019/01/09.
- Motterle G, Ahmed ME, Andrews JR, et al. Tumor seeding after robot-assisted radical prostatectomy: literature review and experience from a single institution. *J Urol*. 2020;203:1141–1146. <https://doi.org/10.1097/JU.0000000000000701>, 2019/12/18.
- Tran G, Parrinello D, Dalal I. Laparoscopic port-site metastasis from prostate cancer on 18F-fluciclovine PET/CT. *Clin Nucl Med*. 2021;46:e279–e281. <https://doi.org/10.1097/RLU.0000000000003407>, 2020/11/20.
- Shaygan B, Zukotynski K, Benard F, et al. Canadian Urological Association best practice report: prostate-specific membrane antigen positron emission tomography/computed tomography (PSMA PET/CT) and PET/magnetic resonance (MR) in prostate cancer. *Can Urol Assoc J*. 2021;15:162–172. <https://doi.org/10.5489/cuaj.7268>, 2021/03/05.
- De Bruyne P, Schatteman P, De Naeyer G, et al. Port site metastasis in prostate cancer. *Can Urol Assoc J*. 2015;9:E387–E389. <https://doi.org/10.5489/cuaj.2768>, 2015/08/01.
- Clarebrough E, Duncan C, Christidis D, et al. PSMA-PET guided hook-wire localization of nodal metastases in prostate cancer: a targeted approach. *World J Urol*. 2019;37:1251–1254. <https://doi.org/10.1007/s00345-018-2282-y>, 2018/04/05.