

From intramural ectopic pregnancy to hysterectomy: A case report

Author

Harris, R, Awal, W, Jacob-Rogers, S, Walker, G

Published

2024

Journal Title

Case Reports in Women's Health

Version

Version of Record (VoR)

DOI

[10.1016/j.crwh.2024.e00600](https://doi.org/10.1016/j.crwh.2024.e00600)

Rights statement


Crown Copyright © 2024 Published by Elsevier B.V. This is an open access article under the CC BY-NC-ND license (<http://creativecommons.org/licenses/by-nc-nd/4.0/>).

Downloaded from

<https://hdl.handle.net/10072/430625>

Griffith Research Online

<https://research-repository.griffith.edu.au>



From intramural ectopic pregnancy to hysterectomy: A case report

Rhys Harris^{a,b,*}, Wasim Awal^a, Sebastian Jacob-Rogers^a, Graeme Walker^a

^a Gold Coast Hospital and Health Service, 1 Hospital Boulevard Southport, QLD 4215, Australia

^b School of Medicine and Dentistry, Griffith University, 1 Parklands Dr, Southport, QLD 4215, Australia

ARTICLE INFO

Keywords:

Intramural ectopic pregnancy
Myometrial ectopic pregnancy
Methotrexate
Arteriovenous malformation
Case report

ABSTRACT

An intramural ectopic pregnancy is one of the rarest types of ectopic pregnancy, and due to the scarcity of reported cases there are no clear guidelines regarding diagnosis and management of the condition. We report a case of a non-viable intramural ectopic pregnancy managed with intravenous methotrexate, in a patient with no previous pregnancies but a history of uterine cornual cyst excision. The patient subsequently developed a uterine arteriovenous malformation, which was embolised. Following this, she had two pregnancies, one culminating in an elective caesarean section at term, and the other a medical termination of pregnancy at 19 weeks of gestation. As a result of post-traumatic stress disorder attributed to this complicated history, the patient requested a hysterectomy. This case demonstrates the complexity of the management of intramural ectopic pregnancy and highlights the impacts the condition can have on a patient's physical and mental health.

1. Introduction

An intramural (or myometrial) ectopic pregnancy is where a pregnancy implants into the myometrium of the uterus, without connection to the endometrial cavity, fallopian tubes, or round ligament [1]. It is estimated that of all ectopic pregnancies, intramural ones account for less than 1% of cases; however, it is difficult to estimate the true prevalence [2]. There are approximately 70 reported cases in the literature and therefore data and research are limited [3].

Symptoms of an intramural ectopic pregnancy are often non-specific; they include abdominal pain, vaginal bleeding and amenorrhoea. Some cases are asymptomatic, which can make diagnosis difficult. Differential diagnoses include gestational trophoblastic disease (GTD), other types of ectopic pregnancy, miscarriage of intrauterine pregnancy and arteriovenous malformation (AVM) [1,4].

Diagnosis typically is made with a positive beta human chorionic gonadotropin (HCG) test and either ultrasound or magnetic resonance (MR) imaging. The endometrial and myometrial junction needs to be visualised when imaging to make the diagnosis [5]. In some cases, the diagnosis is not made until the time of surgery [3].

It is unclear what causes intramural ectopic pregnancy; however, it is believed that previous uterine surgery (including caesarean section, dilatation and curettage, and myomectomy) is a risk factor as it can create microscopic sinus tracts that allow implantation of the pregnancy

in the myometrium [5].

Due to scarcity of cases, no clear guidelines exist regarding management; however, medical treatment can include systemic or localised methotrexate (which may include potassium chloride injection), while surgical management may be with uterine wedge resection or hysterectomy [6]. Decisions about management also depend on the gestation, extent of myometrial involvement, viability, desires for future fertility, and whether the pregnancy is wanted [5].

Reported consequences of intramural ectopic pregnancies include uterine rupture, haemorrhage and hysterectomy. There are also case reports of other types of ectopic pregnancy (including interstitial and caesarean scar ectopic pregnancy) being associated with acquired arteriovenous malformations [7,8].

2. Case Presentation

A 30-year-old woman, G1 P0, presented to the emergency department at 10 weeks of gestation with vaginal bleeding and a pregnancy of unknown location on community ultrasound, having been trying to conceive for more than 12 months.

The patient had significant gynaecological history, including a laparotomy and right salpingo-oophorectomy for a stage 1 A mucinous ovarian tumour at age 19. At age 24, she had a subsequent laparoscopic excision of endometriosis, and subsequent repeat laparotomy for

* Corresponding author at: Gold Coast Hospital and Health Service, 1 Hospital Boulevard Southport, QLD 4215, Australia.

E-mail addresses: rhys.harris@health.qld.gov.au (R. Harris), wasim.awal@health.qld.gov.au (W. Awal), sebastian.jacob-rogers@health.qld.gov.au (S. Jacob-Rogers), graeme.walker@health.qld.gov.au (G. Walker).

<https://doi.org/10.1016/j.crwh.2024.e00600>

Received 8 March 2024; Received in revised form 23 March 2024; Accepted 25 March 2024

Available online 26 March 2024

2214-9112/Crown Copyright © 2024 Published by Elsevier B.V. This is an open access article under the CC BY-NC-ND license (<http://creativecommons.org/licenses/by-nc-nd/4.0/>).

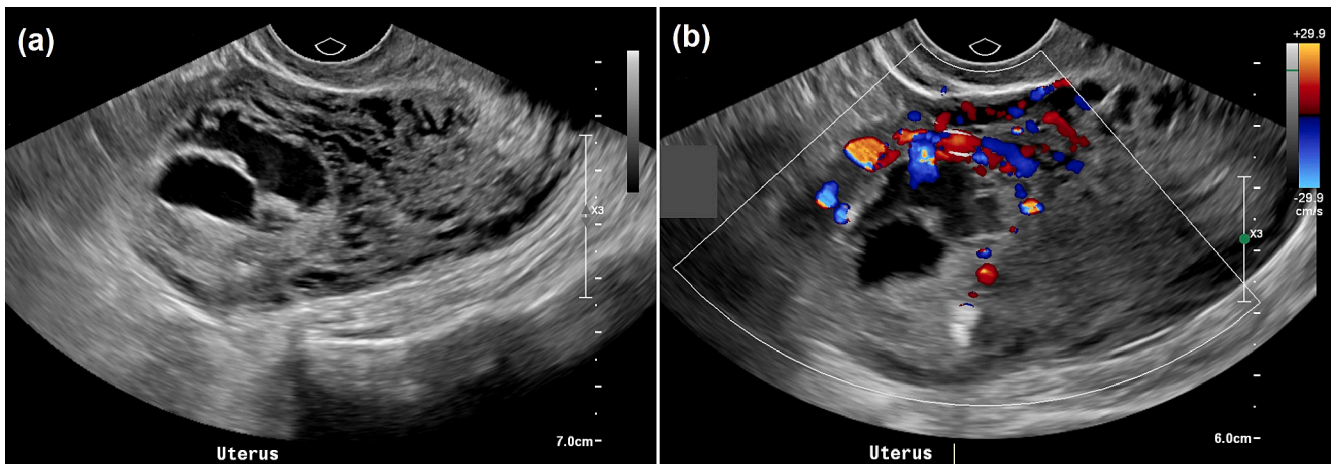


Fig. 1. (a) Transvaginal ultrasound of the uterus demonstrating irregular cystic spaces in the anterior myometrium. (b) The surrounding areas are hypervascular on colour Doppler.

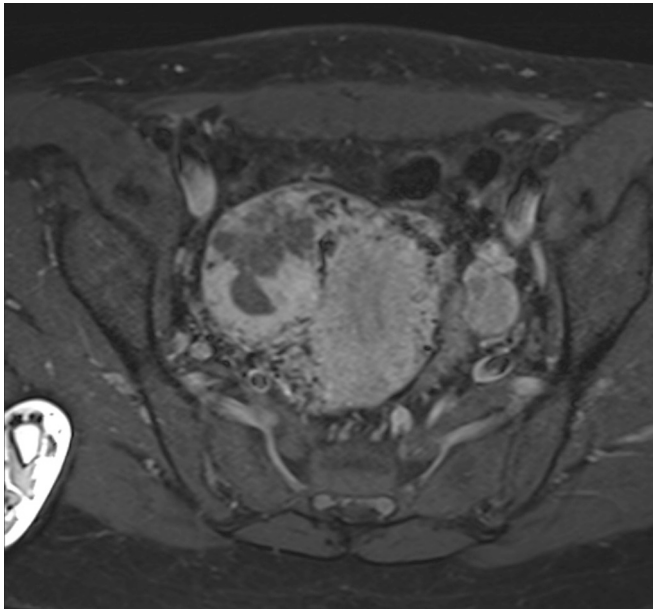


Fig. 2. Axial fat-saturated T1-weighted MRI sequence, after administration of IV gadolinium. This demonstrates a peripherally enhancing solid-cystic mass measuring $3.5 \times 3.8 \times 4.2$ cm. It is located in the right uterine body myometrium and is partially subserosal. Vascularity was not concerning for an arteriovenous malformation.

removal of a right cornual cyst (benign histology), which was excised similar to a myomectomy. It was not documented if there was any breach of the uterine cavity or not during this procedure.

Repeat ultrasound (Fig. 1) demonstrated no intrauterine or extrauterine pregnancy, but an abnormality in the myometrium of the anterior uterine body, with differential diagnoses of a uterine AVM, invasive GTD, with myometrial varices from pelvic congestion thought less likely.

The patient was admitted by gynaecology and underwent an MR scan of the pelvis (Fig. 2), which demonstrated an unusual right lateral solid, cystic mass measuring up to 4.2 cm that was not related to the endometrial cavity, but rather subserosal and intramural, separate to the uterine cornua. The MR scan was reported as suspicious for a myometrial ectopic pregnancy, with other differentials of an AVM, GTD or an unusual fibroid being thought less likely. The pregnancy was nonviable, with no fetal heart rate detected on imaging. The patient's beta

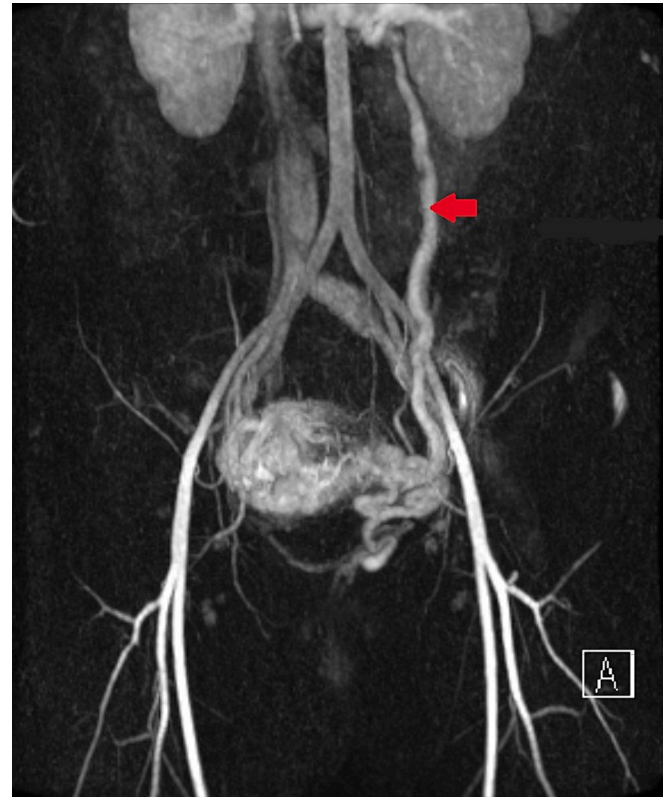


Fig. 3. Coronal time-resolved MR angiography with stochastic trajectories (TWIST) demonstrates tortuous uterine vessels surrounding the lesion followed by early filling of a dilated left ovarian vein. This raises the possibility of an arteriovenous malformation.

HCG dropped from 9246 to 6135.

The patient subsequently underwent management with IV methotrexate and was discharged two days later. Repeat MR scan 5 days after the administration of methotrexate demonstrated minimal interval decrease in the size of the intramural ectopic pregnancy; however, vascularity raised the possibility of a developing AVM (Fig. 3). The patient was followed up in the early-pregnancy clinic with serial weekly beta HCG tests until negative, and serial ultrasound scans.

Repeat MR and CT angiogram 4 months post-methotrexate demonstrated further interval decrease in size of the myometrial lesion, but

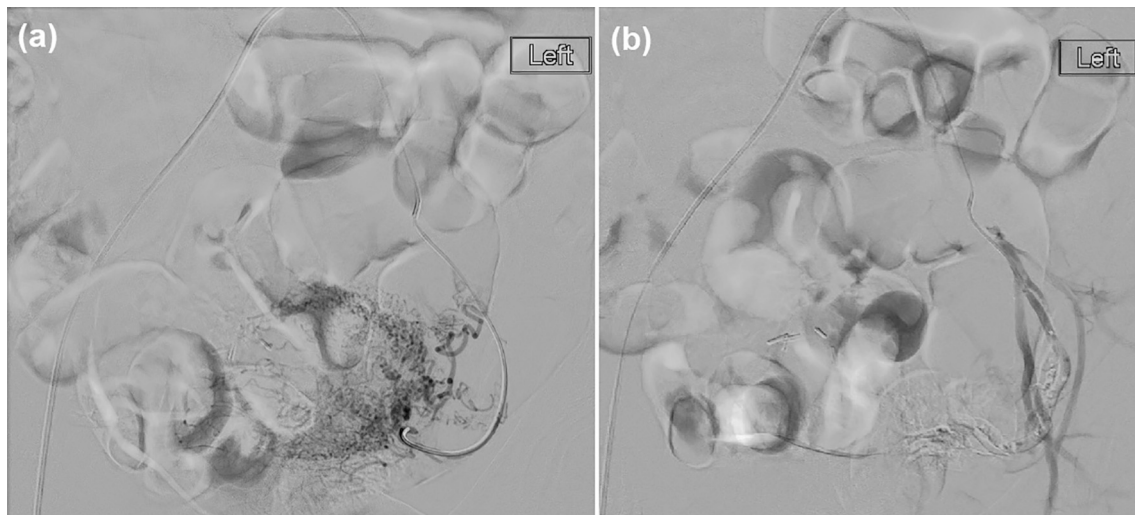


Fig. 4. (a) Catheter-directed angiography of the left uterine artery demonstrates tortuosity of the left uterine vessels surrounding the lesion and early opacification of the left ovarian vein. (b) Repeat angiographic run after administration of a gelfoam slurry demonstrates greatly reduced flow through the left uterine artery.

showed a progression of the AVM. The patient was consented for and underwent uterine artery embolisation by interventional radiology (Fig. 4). Follow-up imaging 7 months post-methotrexate demonstrated scarring at the site of the previous ectopic pregnancy location but no large vessels or collection. The patient was discharged from the gynaecology clinic, referred for in vitro fertilisation due to her previous difficulty conceiving, and advised to present for an early ultrasound in any subsequent pregnancy. She was also advised that she would require a caesarean section for any future pregnancy.

Twelve months post-methotrexate the patient presented with a spontaneous conception of a viable intrauterine pregnancy. She had a low-risk non-invasive prenatal test (NIPT), and was case managed by the maternal fetal medicine (MFM) team and underwent serial scans at 13, 16, 20, 24, 28, 32, and 36 weeks. Scans were unremarkable apart from the presence of a single umbilical artery, with no evidence of placenta accreta spectrum. The pregnancy was uncomplicated until an admission at 36 weeks and 6 days of gestation due to constant abdominal pain and a syncopal episode. The patient was booked for and underwent an elective lower segment caesarean section at 37 weeks 1 day. The caesarean section was uncomplicated with delivery of a live baby, estimated blood loss of 300 mL, and minimal adhesions despite previous surgeries. The patient was discharged after the caesarean with contraceptive advice provided.

The patient represented 9 months after the caesarean section requesting a termination of an unplanned pregnancy. She had been breastfeeding since the birth of her child and had not had a period since. Ultrasound dated the pregnancy at approximately 19 weeks of gestation. The patient underwent an uncomplicated medical termination of pregnancy with misoprostol in hospital.

Ultimately the patient was seen in the gynaecology clinic and requested a hysterectomy due to post-traumatic stress disorder arising from her complex obstetric and gynaecological history. Requested an elective total laparoscopic hysterectomy and left salpingectomy.

3. Discussion

Given the scarcity of cases, there are currently no clear guidelines outlining the best approach to the diagnosis and management of intramural ectopic pregnancy.

It is highly likely that the patient's previous uterine cyst excision (which was excised in a manner similar to a myomectomy) contributed to the development of the intramural ectopic pregnancy.

Bannon et al. describe a case of an incorrect diagnosis of an

intramural ectopic pregnancy as a missed miscarriage [7]. A patient with no previous pregnancy and a history of a myomectomy presented with a spontaneous conception and ultrasound demonstrating a miscarriage. The patient initially underwent expectant management of the missed miscarriage, with subsequent dilatation and curettage, for which the histology showed no placental villi. Follow-up ultrasound and computed tomography (CT) imaging demonstrated an intramural ectopic pregnancy. The patient underwent management with intravenous systemic methotrexate, but despite this required subsequent laparoscopic excision due to persistent pregnancy tissue on follow-up imaging. Similar to our case, this patient had undergone previous uterine surgery (a myomectomy for a leiomyoma) and it was not clear if the endometrial cavity was entered during that procedure [7]. This highlights the importance of advising patients prior to uterine surgery of the risk (albeit small) of affecting future pregnancy, particularly for patients who desire future fertility.

Among other factors, management should be guided by the fertility desires of the patient. In this case, the patient underwent initial management with methotrexate, a fertility-sparing measure. Ultimately, however, she developed a uterine AVM. While this has been described with other rare types of ectopic pregnancy, including interstitial and caesarean scar ectopic pregnancy, there appear to be no reports in the literature of this occurring in intramural ectopic pregnancy [8,9]. The patient underwent uterine artery embolisation due to the increased size of the AVM, which could potentially have affected her fertility. Despite this, she spontaneously became pregnant thereafter and had a relatively uncomplicated pregnancy course culminating in the delivery of a live, term infant via lower-segment caesarean section.

Ong et al. describe a case of an intramural ectopic pregnancy under medical management [10]. An intramural ectopic pregnancy was diagnosed via ultrasound demonstrating a live fetus. The patient underwent local intra-fetal potassium chloride injection and intra-amniotic methotrexate injection under ultrasound guidance. Beta HCG was down-trending after the procedure, with follow-up ultrasound confirming resolution of the intramural gestational sac.

Unlike in our case, some intramural ectopic pregnancies are diagnosed only at the time of surgery. Kirk et al. reports the case of an intramural ectopic pregnancy which was initially thought to be a tubal ectopic pregnancy [11]. At the time of laparoscopy, an intramural ectopic pregnancy was diagnosed. The management was converted to laparotomy and the pregnancy was excised from the myometrium, posterior, inferior and medial to the fallopian tube origin.

Our case and the cases in the literature highlight that the diagnosis

and management of intramural ectopic pregnancy can be varied, and often management is complicated and prolonged. Our patient describes being very emotionally traumatised from her complex obstetric and gynaecological history. Her desire for hysterectomy is to avoid the possibility of any future pregnancy, and she believes this procedure will also provide emotional closure from the events of the previous few years.

4. Conclusion

This case highlights the complexity of the management of intramural ectopic pregnancies, and demonstrates previous uterine surgery as an important risk factor for this condition. When considering management options, it is important to consider the impacts on fertility, as well as the fact that follow-up and sequelae can be prolonged and can impact on a patient's mental health. Further research is required to develop guidelines for the diagnosis and management of this rare condition.

Contributors

Rhys Harris contributed to conception of the case report, acquiring and interpreting the data, drafting the manuscript, undertaking the literature review and revising the article critically for important intellectual content.

Wasim Awal contributed to conception of the case report, acquiring and interpreting the data, drafting the manuscript, and revising the article critically for important intellectual content.

Sebastian Jacob-Rogers contributed to conception of the case report, acquiring and interpreting the data, drafting the manuscript, and revising the article critically for important intellectual content.

Graeme Walker contributed to patient care, conception of the case report, acquiring and interpreting the data, drafting the manuscript, undertaking the literature review, and revising the article critically for important intellectual content.

All authors approved the final submitted manuscript.

Funding

This work did not receive any specific grant from funding agencies in the public, commercial, or not-for-profit sectors.

Patient consent

The patient provided written informed consent for this case report.

Provenance and peer review

This article was not commissioned and was peer reviewed.

Conflict of interest statement

The authors declare that they have no conflict of interest regarding the publication of this case report.

References

- [1] Q.I. Zhang, X. Xing, S. Liu, X. Xie, X. Liu, F. Qian, Y. Liu, Intramural ectopic pregnancy following pelvic adhesion: case report and literature review, *Arch. Gynecol. Obstet.* 300 (2019 Dec) 1507–1520.
- [2] Y. Wang, F. Yu, L.Q. Zeng, Ectopic pregnancy in uncommon implantation sites: intramural pregnancy and rudimentary horn pregnancy, *Case Rep. Obstet. Gynecol.* (2015 Dec 24) 2015.
- [3] X. Chen, L. Gao, H. Yu, M. Liu, S. Kong, S. Li, Intramural ectopic pregnancy: clinical characteristics, risk factors for uterine rupture and hysterectomy, *Front. Med.* 8 (2021 Oct 28) 769627.
- [4] D.P. Truong, T.H. Pham, P.N. Nguyen, Q.N. Ho, Misdiagnosis of intramural ectopic pregnancy and invasive gestational trophoblastic disease on ultrasound: a challenging case at Tu Du Hospital in Vietnam in COVID-19 pandemic peak and mini-review of literature, *Radiol. Case Rep.* 17 (12) (2022 Dec 1) 4821–4827.
- [5] M. Memtsa, A. Jamil, N. Sebire, E. Jauniaux, D. Jurkovic, Diagnosis and management of intramural ectopic pregnancy, *Ultrasound Obstet. Gynecol.* 42 (3) (2013 Sep) 359–362.
- [6] D. Vagg, L. Arsala, S. Kathurasinghe, W.C. Ang, Intramural ectopic pregnancy following myomectomy, *J. Investig. Med. High Impact Case Rep.* 6 (2018 Jul 19), 2324709618790605.
- [7] K. Bannon, C. Fernandez, D. Rojas, E.M. Levine, S. Locher, Diagnosis and management of intramural ectopic pregnancy, *J. Minim. Invasive Gynecol.* 20 (5) (2013 Sep 1) 697–700.
- [8] G. Shafqat, A. Khan, S. Basharat, Uterine arteriovenous malformation complicating a scar ectopic pregnancy, *Radiol. Case Rep.* 17 (5) (2022 May 1) 1670–1673.
- [9] C.J. Lin, L.W. Huang, Y.H. Lin, J.L. Hwang, K.M. Seow, Interstitial ectopic pregnancy complicated by uterine arteriovenous malformations treated with unilateral transarterial embolization, *Taiwan. J. Obstet. Gynecol.* 53 (2) (2014 Jun 1) 279–281.
- [10] C. Ong, L.L. Su, D. Chia, M. Choolani, A. Biswas, Sonographic diagnosis and successful medical management of an intramural ectopic pregnancy, *J. Clin. Ultrasound* 38 (6) (2010 Jul) 320–324.
- [11] E. Kirk, K. McDonald, J. Rees, A. Govind, Intramural ectopic pregnancy: a case and review of the literature, *Eur. J. Obstet. Gynecol. Reprod. Biol.* 168 (2) (2013 Jun 1) 129–133.