

**Mitral valve bio-prosthesis and annuloplasty thrombosis during extracorporeal membrane oxygenation: Case series**

Author

Challa, A, Latona, J, Fraser, J, Spanevello, M, Scalia, G, Burstow, D, Platts, D

Published

2020

Journal Title

European Heart Journal: Case Reports

Version

Version of Record (VoR)

DOI

[10.1093/ehjcr/ytaa085](https://doi.org/10.1093/ehjcr/ytaa085)

Rights statement

© The Author(s) 2020. Published by Oxford University Press on behalf of the European Society of Cardiology. This is an Open Access article distributed under the terms of the Creative Commons Attribution Non-Commercial License (<http://creativecommons.org/licenses/by-nc/4.0/>), which permits non-commercial re-use, distribution, and reproduction in any medium, provided the original work is properly cited.






Downloaded from

<http://hdl.handle.net/10072/399066>

Griffith Research Online

<https://research-repository.griffith.edu.au>

# Mitral valve bio-prosthesis and annuloplasty thrombosis during extracorporeal membrane oxygenation: case series

Abhinay Challa <sup>1,2\*</sup>, Jilani Latona <sup>1</sup>, John Fraser<sup>3,4</sup>, Michelle Spanevello <sup>3,5</sup>, Gregory Scalia<sup>1,3</sup>, Darryl Burstow <sup>1,3</sup>, David Platts <sup>1,3,4</sup>

<sup>1</sup>Department of Cardiology, The Prince Charles Hospital, Chermside, 4032 Brisbane, Australia; <sup>2</sup>Bond University, Robina, 4226 Gold Coast, Australia; <sup>3</sup>University of Queensland, St Lucia, 4072 Brisbane, Australia; <sup>4</sup>Critical Care Research Group, The Prince Charles Hospital, Chermside, 4032 Brisbane, Australia; and <sup>5</sup>Department of Haematology, Cancer Care Services, Royal Brisbane and Women's Hospital, Herston, 4029 Brisbane, Australia

Received 20 July 2019; first decision 29 August 2019; accepted 23 March 2020; online publish-ahead-of-print 24 April 2020

## Background

Veno-arterial extracorporeal membrane oxygenation (VA-ECMO) is a well-recognized form of haemodynamic support for patients with refractory cardiogenic shock, who are unable to be weaned off cardiopulmonary bypass. Thrombosis or bleeding from cannula sites or surgical wounds are the leading cause of morbidity and mortality in these patients, and presents a delicate balance of anticoagulation during management of patients undergoing circulatory support.

## Case summary

In this case series, we discuss three cases of patients undergoing mitral valve replacements or repair with thrombosis of their new bio-prosthesis in the immediate post-operative setting. All three patients were supported with VA-ECMO post-operatively, and thrombosis occurred despite anticoagulation.

## Discussion

During extracorporeal membrane oxygenation, the reduced flow throughout the heart increases the risk of intracardiac thrombosis. This is of particular importance in the context of mitral valve replacements and repairs, where the bio-prosthesis is an additional risk factor for thrombosis. Our cases demonstrate the morbidity and mortality of such complications, with the likely aetiology being low transvalvular flow in a newly inserted valve combined with the pro-thrombotic state created by the VA-ECMO circuit.

## Keywords

Extracorporeal membrane oxygenation • VA-ECMO • Mitral valve • Thrombosis • Case series

## Learning points

- Patients undergoing VA-ECMO support are at significant risk of thrombosis, which is of particular importance in the context of mitral valve replacement or repair, where the prosthesis is an additional risk factor.
- The likely aetiology of thrombosis is low transvalvular flow in a newly inserted valve combined with the pro-thrombotic state created by the VA-ECMO circuit.
- Vigilant monitoring with transthoracic echocardiography or transesophageal echocardiography may be warranted in this cohort to detect early mitral valve thrombus formation, which may significantly impact on patient management.

\* Corresponding author. Tel: 0432696511, Email: [abhinay.challa@hotmail.com](mailto:abhinay.challa@hotmail.com)

Handling Editor: Pankaj Garg

Peer-reviewers: Alberto Bouzas-Mosquera, Aref Bin Abdulhak, and Dejan Milasinovic

Compliance Editor: Stefan Simovic

Supplementary Material Editor: Deepti Ranganathan

© The Author(s) 2020. Published by Oxford University Press on behalf of the European Society of Cardiology.

This is an Open Access article distributed under the terms of the Creative Commons Attribution Non-Commercial License (<http://creativecommons.org/licenses/by-nc/4.0/>), which permits non-commercial re-use, distribution, and reproduction in any medium, provided the original work is properly cited. For commercial re-use, please contact [journals.permissions@oup.com](mailto:journals.permissions@oup.com)

## Introduction

Veno-arterial extracorporeal membrane oxygenation (VA-ECMO) is a well-recognized form of haemodynamic support for selected patients with cardiogenic shock.<sup>1</sup> Thrombosis is a significant complication during VA-ECMO support and can occur in the circuit, oxygenator, pump, cannulae, and the ventricle, with a reported incidence described up to 17%.<sup>2</sup> The increased afterload generated by VA-ECMO along with significantly reduced cardiac contractility reduces flow throughout the heart, increasing the risk of intra-cardiac and aortic root thrombosis. This is of importance in the context of mitral valve replacement or repair, where the prosthesis is an additional risk factor for thrombosis.

In addition to thrombosis, bleeding from cannula sites or surgical sites are also a common cause of morbidity and mortality in patients during VA-ECMO, which represents a significant management challenge in appropriately balancing the risks of thrombosis and bleeding in patients undergoing circulatory support.<sup>2</sup>

We present two cases of early bioprosthetic mitral valve dysfunction and one case of early mitral annuloplasty dysfunction secondary to thrombosis in patients with post-operative VA-ECMO support.

destruction due to multiple large vegetations extending along the length of the aorto-mitral curtain. Echocardiography also revealed a severely dilated left ventricle, with an ejection fraction of 40% in the context of moderate mitral regurgitation. The left atrium was moderately dilated and there was concomitant moderate right ventricular dilatation and systolic dysfunction.

The patient underwent urgent cardiac surgery and a 27 mm Mosaic<sup>®</sup> Medtronic mitral valve replacement, 21 mm Edwards Perimount aortic valve replacement, and an aorto-mitral curtain reconstruction was performed. The patient was rested on cardiopulmonary bypass (CPB) for 1 h, and failed to wean from CPB due to biventricular failure despite inotropic support with 0.1 µg/kg/min adrenaline and noradrenaline, 0.01 units/min vasopressin, inhaled nitric oxide, and intra-aortic balloon pump (IABP) insertion. Central VA-ECMO with flow rates ~4 L/min was initiated for haemodynamic support with IABP still *in situ*, and anticoagulation with unfractionated heparin was initiated ~12 h post-operatively with a target activated partial thromboplastin time (APTT) of 50–60 s. Immediate post-operative TEE demonstrated pulsative flow without evidence of spontaneous echo contrast (SEC). Inotropes and IABP were continued with VA-ECMO to optimize native cardiac flow and minimize the risk of intra-cardiac thrombosis.

## Timeline

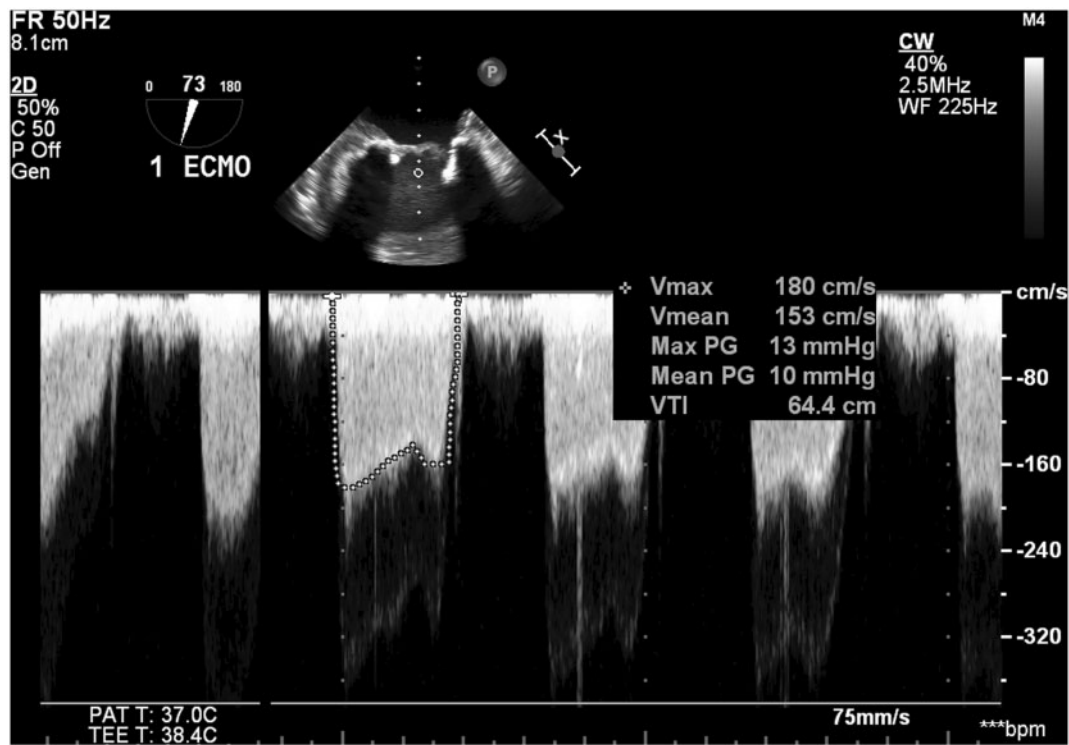
Patient	Presentation	Diagnosis	Intervention	Complication to bio-prosthesis	Outcome
1	Syncope	Infective endocarditis with cardiogenic shock	Bioprosthetic aortic and mitral valve replacement with aorto-mitral curtain reconstruction	Thrombosis causing two immobile leaflets and mitral stenosis	Deceased
2	Chest pain	Late presentation STEMI with ventricular septal defect (VSD)	Repair of VSD and bioprosthetic mitral valve replacement	Leaflet thrombosis causing mitral stenosis	Followed up for 7 years. Residual mild mitral stenosis
3	Shortness of breath	Severe mitral regurgitation secondary to prolapse of anterior mitral leaflet	Mitral valve annuloplasty	Thrombosis of leaflets extending to chordae	Followed up for 2 years with mild mitral regurgitation without significant stenosis

## Case presentation

In Case 1, a 28-year-old male with no medical co-morbidities and a history of intravenous drug use 2 days prior presented to hospital with syncope. On examination, he was febrile, tachycardic, and hypotensive with a blood pressure of 70/40 mmHg despite fluid resuscitation, and auscultation revealed a pan diastolic murmur. His electrocardiogram showed ST segment depression and T-wave inversion in lateral leads with poor R-wave progression across the precordial leads, and his initial Troponin I was 0.83 µg/L. Intravenous dobutamine and noradrenaline was initiated and transthoracic echocardiography (TTE) and transesophageal echocardiography (TEE) showed severe aortic regurgitation and extensive aortic valve

However, on post-operative Day 4, TEE was performed revealing mitral leaflet thrombosis with two of the three leaflets being immobile (Supplementary material online, Videos S1–S3), and a stroke volume of 31 mL. As a result, there was functional mitral stenosis with a diastolic mean gradient of 10 mmHg (Figure 1). Importantly, there was no evidence of overt disseminated intravascular coagulation as a potential cause of thrombosis, with the patient's platelets, fibrinogen, and prothrombin time within the normal reference ranges, and an APTT of 55 s reflective of the ongoing heparin infusion.

The patient subsequently failed to be weaned off ECMO, with minimal change in left ventricular systolic volume, persistent severe right ventricular dysfunction, and vasoplegia despite multiple inotropes and IABP. With plateauing recovery, along with ongoing incremental



**Figure 1** Mitral stenosis with diastolic mean gradient of 10 mmHg across bio-prosthetic mitral valve.

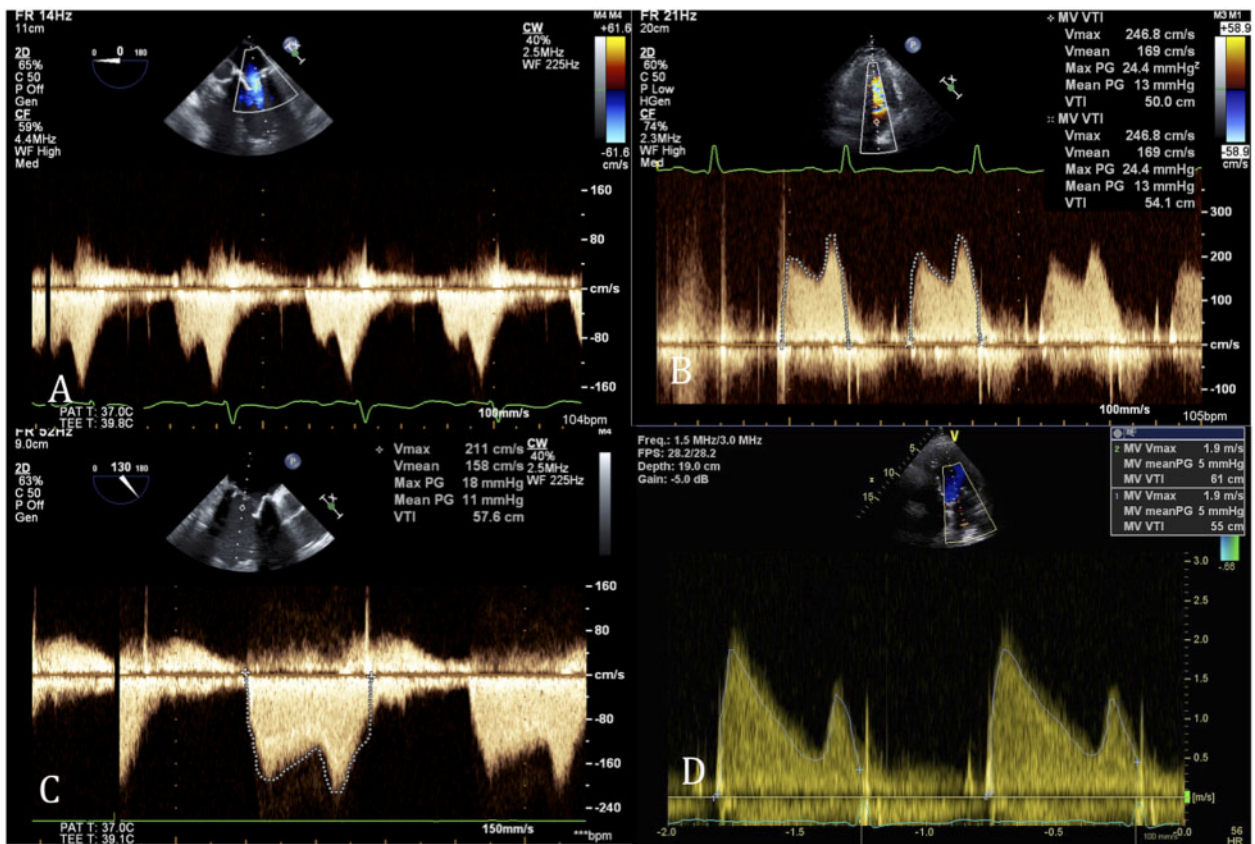
risks of VA-ECMO as demonstrated by the bioprosthetic mitral valve thrombosis, it was deemed that further intervention with thrombolysis or valve in valve surgery would be futile, and the patient died shortly after cessation of circulatory support.

In Case 2, a 62-year-old male with a background history of hypertension and hyperlipidaemia presented to hospital with a week history of intermittent chest pain, and worsening shortness of breath over the preceding 24 h. On examination, he was hypotensive with a blood pressure of 80/50 mmHg, tachycardic, and auscultation revealed a pan systolic murmur. His electrocardiogram showed inferior Q waves and ST elevation, with reciprocal ST segment depression in anterior leads. His initial laboratory results showed an elevated Troponin I of 5 µg/L, creatinine of 300 µmol/L and liver transaminase levels >1500 U/L. He underwent urgent coronary angiography that demonstrated an occluded mid right coronary artery, and echocardiography demonstrated a 5 cm ventricular septal defect (VSD) (Supplementary material online, Videos S4 and S5). He had multi-organ failure despite haemodynamic support with dobutamine and noradrenaline and hence peripheral VA-ECMO with an unfractionated heparin infusion was commenced. Following improvement in multi-organ dysfunction 3 days later, the patient underwent a VSD repair. During the VSD repair, there was significant resection of the anterior mitral valve leaflet and the sub-valvular apparatus, which necessitated a mitral valve replacement which was performed with a 27 mm Mosaic® Medtronic bio-prosthesis. Veno-arterial extracorporeal membrane oxygenation was continued post-operatively at a

flow rate of ~4.5 L/min with ongoing heparin infusion with a target APTT of 50–65 s.

On post-operative Day 1, a TEE was performed which showed a low flow state throughout the heart with stroke volume of 20 mL with mild restriction of mitral valve leaflet opening, without significant stenosis. On post-operative Day 3, thrombocytopenia with a platelet count of  $35 \times 10^9/L$  was detected with a 4 T score in keeping with an intermediate probability of heparin-induced thrombotic thrombocytopenia. Subsequent testing with enzyme-linked immunoassays detected heparin PF4 antibodies confirming heparin-induced thrombotic thrombocytopenia syndrome and the heparin infusion was changed to lepirudin. Transesophageal echocardiography was repeated 4 days post-operatively and demonstrated thickened bio-prosthetic mitral valve leaflets with a fixed posteromedial leaflet secondary to leaflet thrombosis. This resulted in functional mitral stenosis (Supplementary material online, Videos S6 and S7). The patient was commenced on warfarin and successfully weaned off VA-ECMO. Follow-up TEE on post-operative Day 12 showed moderate leaflet thrombosis induced mitral stenosis with a diastolic mean gradient of 11 mmHg. The patient was discharged with long-term warfarin therapy and outpatient follow-up showed gradual improvement in thrombotic mitral stenosis with a diastolic mean gradient of 5 mmHg (Figure 2 and Supplementary material online, Video S8) and ejection fraction of 43% 7 years post-procedure.

In Case 3, a 49-year-old female with a background of Marfan Syndrome underwent an elective mitral valve annuloplasty with a



**Figure 2** Doppler of mitral stenosis according to post-operative days (POD): (A) POD 1 TEE Doppler with mean gradient 3.6 mmHg. (B) POD 11 TTE Doppler with mean gradient 13 mmHg (C). POD 12 TEE Doppler with mean gradient 11 mmHg. (D) Follow-up TTE 7 years post-operatively with Doppler mean gradient 5 mmHg.

38 mm Edwards Lifesciences® C-E Physio mitral ring for severe prolapse of the anterior mitral valve leaflet. The surgery was indicated for progressive dyspnoea, with the patient experiencing breathlessness on minimal exertion. Her examination demonstrated dual heart sounds with a late peaking systolic murmur audible at the cardiac apex, clear lung fields and no evidence of peripheral oedema. Her blood pressure was 130/70 mmHg, and pre-operative laboratory results were within normal ranges. Her electrocardiogram demonstrated sinus rhythm, with inferior and lateral T-wave inversion, and her TTE showed severe LV dilatation with an ejection fraction of 45%, and a severely dilated left atrium. Post-operatively the patient developed atrial fibrillation, and had significant right ventricular dysfunction and was unable to be weaned off CPB despite inotropic support with adrenaline 0.15 µg/kg/min, milrinone 0.5 µg/kg/min, inhaled nitric oxide and insertion of IABP. Decision was made to transition to peripheral VA-ECMO, with a heparin infusion with target APTT of 40–50 s. For the following 3 days, the VA-ECMO flows were lower than anticipated (~2 L/min), thought to be secondary to inadequate venous drainage due to a 6 mm thrombus on the venous cannula.

Post-operative TEE on Day 3 revealed irregularly thickened mitral valve leaflets, with thickening extending to chordae consistent with thrombosis (Supplementary material online, Video S9 and S10).

Echocardiography demonstrated pulsatile flow with no SEC visualized, as well as mild mitral regurgitation without evidence of mitral stenosis. In order to optimize transvalvular flow, inotropes were utilized and the IABP was continued, which facilitated weaning of VA-ECMO. The patient had a prolonged ICU stay with a slow wean off inotropes, IABP removal and was discharged from ICU 21 days post-operatively and was maintained on a single antiplatelet agent. Follow-up transthoracic echocardiography 2 years post-surgery revealed an ejection fraction of 51%, and the mitral valve had a transvalvular diastolic mean gradient of 2 mmHg and mild regurgitation.

## Discussion

Bioprosthetic valve and annuloplasty thrombosis is an uncommon occurrence, with a particular paucity of literature in the acute post-operative period.<sup>3</sup> Risk factors for bioprosthetic thrombosis include low cardiac output, left atrial dilatation, atrial fibrillation, and hypercoagulability.<sup>4</sup> An important risk factor for bioprosthetic valve thrombosis is the low transvalvular flow as a consequence of VA-ECMO.<sup>5</sup> These effects were compounded by the prothrombotic state of heparin-induced thrombotic thrombocytopenia syndrome in Case 2.

Furthermore, the VA-ECMO circuit itself causes shear stress to circulating red blood cells and haemostatic proteins. As a result, patients develop an acquired Von Willebrand syndrome<sup>6</sup> as well significant platelet dysfunction.<sup>7</sup> Coupled with activation of coagulation pathways, VA-ECMO creates a prothrombotic state,<sup>8</sup> illustrated by the development of a thrombus on the venous cannula despite a heparin infusion in Case 3. The development of post-operative atrial fibrillation as well as pre-existing severe left atrial dilatation were further risk factors for developing mitral leaflet thrombosis, despite the low VA-ECMO flow rates. Of note, in all three of our cases, there was pulsatile flow and no significant SEC demonstrated on post-operative TEE.

In the literature, there are only a few cases describing acute post-operative thrombosis in bioprosthetic mitral valves during VA-ECMO, one of which is a case series by Kagiyama *et al.*<sup>9</sup> that describes two patients. In the first case, thrombus was visualized on histological examination on the explanted valve and in the second case thrombus was assumed after severe stenosis improved post-urokinase infusion. Another case report by Dahl *et al.*<sup>10</sup> demonstrates the difficulty of balancing bleeding and thrombosis risk, where anticoagulation was ceased post-bioprosthetic mitral valve replacement while the patient was supported with VA-ECMO due to concerns of an upper gastrointestinal bleed. Compounded by the risk factor of atrial flutter, the patient developed mitral valve thrombosis detected by early TEE which showed leaflet thickening and an elevated mitral transvalvular gradient, leading to an early salvage operation.

Imada *et al.*<sup>11</sup> published a case of early bioprosthetic mitral valve thrombosis during VA-ECMO and the authors similarly postulated that the likely aetiology was a combination of cardiogenic shock and retrograde perfusion from the VA-ECMO circuit despite using anticoagulation therapy. Another case series by Glaser *et al.*<sup>12</sup> describes two cases of bioprosthetic mitral valve failure secondary to fusion of mitral leaflet cusps during VA-ECMO. In both of these cases, the mitral valve was explanted and did not show any thrombus formation.

Left ventricular distension, inadequate left ventricular ejection and consequent stasis of blood within the heart can occur during support with VA-ECMO. This can then lead to intra-cardiac and aortic root thrombosis. Strategies to try and minimize these effects include the use of lower flow VA-ECMO, short-term percutaneous mechanical support devices (such as IABP and Impella<sup>®</sup>) as well as the addition of inotropic drugs.<sup>13</sup> However, such interventions do not eliminate this risk of thrombosis and these patients are challenging to manage.

## Conclusion

Patients undergoing VA-ECMO support are at significant risk of thrombosis, which is of particular importance in the context of mitral valve replacement or repair, where the prosthesis is an additional risk factor. Our cases demonstrate the morbidity and mortality of such complications, with the likely aetiology being low transvalvular flow across a new mitral bio-prosthesis combined with the prothrombotic state created by the VA-ECMO circuit. Potential strategies to maximize intra-cardiac blood flow include utilization of lower flow VA-ECMO, insertion of short-term percutaneous mechanical support devices and inotropic therapy. Vigilant monitoring with TTE or TEE may be warranted in this cohort to detect early mitral valve

thrombus formation. In selected patients, this may indicate thrombolytic therapy, long-term anticoagulation in haemodynamically stable patients or early salvage operations to minimize long-term morbidity and mortality.<sup>14–16</sup>

## Lead author biography



Dr Abhinav Challa is a Cardiology Advance Trainee currently working at the Prince Charles Hospital. He has completed his medical degree through Bond University, and subsequently completed a Masters of Medicine (Clinical Epidemiology) through the University of Sydney. He has a special interest in echocardiography, Advanced Heart Failure and Structural Intervention.

## Supplementary material

Supplementary material is available at *European Heart Journal - Case Reports* online.

**Slide sets:** A fully edited slide set detailing this case and suitable for local presentation is available online as [Supplementary data](#).

**Consent:** The authors confirm that written consent for submission and publication of this case report including image(s) and associated text has been obtained from the patient in line with COPE guidance.

**Conflict of interest:** none declared.

## References

- Rastan AJ, Dege A, Mohr M, Doll N, Falk V, Walther T, Mohr FW. Early and late outcomes of 517 consecutive adult patients treated with extracorporeal membrane oxygenation for refractory postcardiotomy cardiogenic shock. *J Thorac Cardiovasc Surg* 2010;**139**:302–311, 311.e1.
- Murphy DA, Hockings LE, Andrews RK, Aubron C, Gardiner EE, Pellegrino VA, Davis AK. Extracorporeal membrane oxygenation-hemostatic complications. *Transfus Med Rev* 2015;**29**:90–101.
- Tsiouris A, Neme H, Borgi J. Early acute thrombosis of bioprosthetic mitral valve presenting with cardiogenic shock. *Gen Thorac Cardiovasc Surg* 2013;**61**:152–154.
- Korkolis DP, Passik CS, Marshalko SJ, Koullias GJ. Early bioprosthetic mitral valve “pseudostenosis” after complete preservation of the native mitral apparatus. *Ann Thorac Surg* 2002;**74**:1689–1691.
- Gottfried R, Paluszkiwicz L, Kizner L, Morshuis M, Koertke H, Gummert J. Thrombosis of a bioprosthetic mitral valve under extracorporeal membrane oxygenation: thrombus formation in the left heart. *Ann Thorac Surg* 2012;**94**:657.
- Tauber H, Ott H, Streif W, Weigel G, Loacker L, Fritz J, Heinz A, Velik-Salchner C. Extracorporeal membrane oxygenation induces short-term loss of high-molecular-weight von Willebrand factor multimers. *Anesth Analg* 2015;**120**:730–736.
- Cheung PY, Sawicki G, Salas E, Etches PC, Schulz R, Radomski MW. The mechanisms of platelet dysfunction during extracorporeal membrane oxygenation in critically ill neonates. *Crit Care Med* 2000;**28**:2584–2590.
- Oliver WC. Anticoagulation and coagulation management for ECMO. *Semin Cardiothorac Vasc Anesth* 2009;**13**:154–175.
- Kagiyama N, Okura H, Nezu S, Kawamoto T, Murakami T, Hashimoto Y, Tanemoto K, Yoshida K. Two cases of acute bioprosthetic mitral valve thrombosis immediately after mitral valve replacement. *Circulation* 2014;**129**:e328–e330.

10. Dahl AB, Gregory SH, Ursprung E, Kawabori M, Couper GS, Hueneker R. Acute presentation of bioprosthetic mitral valve thrombosis in a patient on venoarterial extracorporeal membranous oxygenation. *J Cardiothorac Vasc Anesth* 2019;**33**: 844–849.
11. Imada T, Shibata SC, Okitsu K, Fujino Y. Unexpected bioprosthetic mitral valve thrombus during left ventricular assist device implantation. *JA Clin Rep* 2017;**3**:15.
12. Glaser N, Liska J, Hultman J, Svenarud P. Early bioprosthetic mitral valve failure due to fusion of the cusps. *Ann Thorac Surg* 2013;**96**:699–701.
13. Victor K, Barrett NA, Gillon S, Gowland A, Meadows CI, Ioannou N. Critical care echo rounds: extracorporeal membrane oxygenation. *Echo Res Pract* 2015;**2**: D1–D11.
14. Lengyel M, Fuster V, Keltai M, Roudaut R, Schulte HD, Seward JB, Chesebro JH, Turpie AGG. Guidelines for management of left-sided prosthetic valve thrombosis: a role for thrombolytic therapy. Consensus Conference on Prosthetic Valve Thrombosis. *J Am Coll Cardiol* 1997;**30**:1521–1526.
15. Baumgartner H, Falk V, Bax JJ, Bonis MD, Hamm C, Holm PJ, Jung B, Lancellotti P, Lansac E, Muñoz DR, Rosenhek R, Sjögren J, Mas PT, Vahanian A, Walther T, Wendler O, Windecker S, Zamorano JL. 2017 ESC/EACTS Guidelines for the management of valvular heart disease. *Rev Esp Cardiol (Engl Ed)* 2018;**71**:1–62.
16. Nishimura RA, Otto CM, Bonow RO, Carabello BA, Erwin JP, Fleisher LA, Jneid H, Mack MJ, McLeod CJ, O’Gara PT, Rigolin VH, Sundt TM, Thompson A. 2017 AHA/ACC Focused Update of the 2014 AHA/ACC Guideline for the management of patients with valvular heart disease: a report of the American College of Cardiology/American Heart Association Task Force on Clinical Practice Guidelines. *J Am Coll Cardiol* 2017;**70**:252–289.