

Punching Glass: A 10-Year Consecutive Series

Author

Schaefer, N, Cappello, J, O'Donohue, P, Phillips, A, Elliott, D, Daniele, L

Published

2015

Journal Title

Plastic and Reconstructive Surgery

Version

Version of Record (VoR)

DOI

[10.1097/GOX.0000000000000410](https://doi.org/10.1097/GOX.0000000000000410)

Rights statement

© 2015 American Society of Plastic Surgeons.

Downloaded from

<http://hdl.handle.net/10072/141902>

Griffith Research Online

<https://research-repository.griffith.edu.au>

Punching Glass: A 10-Year Consecutive Series

Nathan Schaefer, MBBS*
 Julie Cappello, MBBS*
 Peter O'Donohue, MBBS*
 Alfred Phillips, MBBS†
 Devlin Elliott, MBChB†
 Luca Daniele, MBBS†

Introduction: Punching glass can cause severe and debilitating injuries. The literature is scant in regards to the injury patterns, optimal management, and preventative strategies. We have reviewed our experience of these injuries at a regional Australian hospital.

Methods: A retrospective chart review of all patients who had punched glass and presented to Cairns Base Hospital between January 2003 and December 2012. Data collected included age, gender, marital status, employment status, alcohol consumption, side of injury, intent, time of presentation, damaged structures, treatment required, operative time, total hospital stay, and required follow-up.

Results: 137 eligible patients were identified during the 10-year study period. Mean age was 26.3 years. Most were men (n = 113), single (n = 122), unemployed (n = 95), and intoxicated (n = 91). Most of these injuries presented outside of normal working hours ($P < 0.001$). Ninety-one patients had superficial skin lacerations only and did not require operative intervention. The remaining 46 patients had a total of 46 tendon, 18 muscle, 12 nerve, 8 vessel and 5 bone injuries, and all required operative intervention. Tendon, nerve and vessel injuries were strongly associated with each other ($P < 0.05$).

Conclusions: This represents the largest case series of glass punching injuries in the English literature. Punching glass can cause significant morbidity in a young age group and is therefore a major public health concern. Thorough physical examination, appropriate imaging and operative repair can improve outcomes. Preventative measures such as stricter legislation and safety glass will reduce the burden of these injuries on the individual and healthcare system in Australia. (*Plast Reconstr Surg Glob Open* 2015;3:e436; doi: 10.1097/GOX.0000000000000410; Published online 23 June 2015.)

Hand injuries are severe and debilitating and can have significant functional and socio-economic consequences. Unfortunately, these injuries are exceedingly common and account for approximately one fifth of all emergency depart-

ment presentations.^{1,2} Glass is the second most likely instrument, after the knife, to be involved in hand injuries.¹ Two percent of hand injuries because of glass are intentionally self-inflicted,³ and glass punching, while rare, is a well-known cause. The literature is scant in regard to the injury patterns, optimal management, and preventative strategies associated with this uncommon mechanism of injury. We present our 10-year experience at a regional Australian hospital. The patient demographics, injury patterns, and management are evaluated over this period. We also explore the legislation concerning glass in Australia and suggest preventative measures to reduce the incidence of these avoidable injuries.

From the *Cairns Hospital, Orthopaedics Department, Cairns North, QLD, Australia; and †Gold Coast University Hospital, Orthopaedics Department, Southport, QLD, Australia.

Received for publication January 9, 2015; accepted May 7, 2015.

Copyright © 2015 The Authors. Published by Wolters Kluwer Health, Inc. on behalf of The American Society of Plastic Surgeons. All rights reserved. This is an open-access article distributed under the terms of the Creative Commons Attribution-NonCommercial-NoDerivatives 3.0 License, where it is permissible to download and share the work provided it is properly cited. The work cannot be changed in any way or used commercially.

DOI: 10.1097/GOX.0000000000000410

Disclosure: The authors have no financial interest to declare in relation to the content of this article. The Article Processing Charge was paid for by the authors.

METHODS

This study received ethical approval from the Human Research Ethics Committee of the Cairns and Hinterland Hospital and Health Service. The medical records of all patients who had punched glass and then presented to the emergency department of Cairns Base Hospital between January 2003 and December 2012 were reviewed retrospectively. Cairns Base Hospital is a 450-bed regional hospital that services the metropolitan, rural, and remote areas of far North Queensland, Australia. The emergency department has approximately 43,000 presentations each year and uses electronic medical documentation.

Patients who had sustained an injury because of punching glass were identified by analyzing the presenting complaint of all the emergency department presentations at Cairns Base Hospital during the study period. The keyword “glass” was used, which produced 1871 separate presentations. This list was analyzed, and 191 patients who had punched glass were identified. Analysis of the medical records revealed incomplete documentation for 54 patients, leaving a total of 137 patients to be included in this study.

Data collected included age, gender, marital status, employment status, alcohol consumption, side of injury, intent, time of presentation, damaged structures, treatment required, operative time, total hospital stay, and required follow-up.

RESULTS

One hundred thirty-seven eligible patients were identified during the study period. Their demographics are displayed in Table 1. Age was analyzed using a binomial test. Binary variables were analyzed using a χ^2 test for goodness of fit.

The time of presentation to the emergency department is displayed in Figure 1. Forty of 137 patients (29.2%) presented during normal working hours (6:00 AM to 6:00 PM), whereas the remaining 97 patients (70.8%) presented outside of normal working hours. When these variables are treated as categorical, during normal working hours versus outside of normal working hours, they are statistically significant ($P < 0.001$) using a 1 sample two-sided binomial test.

Ninety-one patients (66.4%) sustained superficial skin lacerations only, which were able to be treated

Table 1. Patient Demographics

Continuous variable	Mean + SD	
Age	26.3 + 10.7	
Binary variables	No. Patients*	Significance (P)
Gender—male	113/137 (82%)	<0.001
Marital status—single	122/135 (90%)	<0.001
Employment status—unemployed	95/114 (83%)	<0.001
Alcohol intake—intoxicated	91/119 (76%)	<0.001
Hand—dominant	71/102 (70%)	<0.001
Intent—intentional	105/122 (86%)	0.058

*Incomplete medical documentation prevented all variables from being available for every patient.

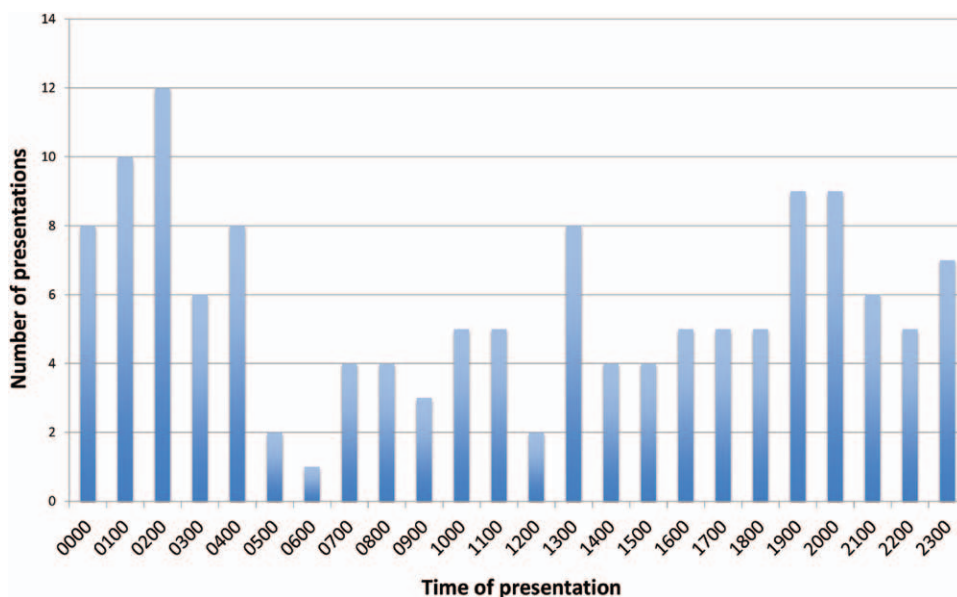


Fig. 1. Time of presentation.

in the emergency department. The remaining 46 patients sustained more significant injuries, which required operative intervention (Table 2). Using statistical analysis to compare the structures injured against all other variables, some correlations are significant (Table 3). Tendon, nerve, and vessel damage are strongly associated with each other ($P < 0.001$).

When the injury was significant enough to require an operation, either a surgical consultant or registrar was the primary operator. A total of 46 operations were required from 137 presentations. Figure 2 displays when these operations were performed. The average duration was 71 minutes with an SD of 40 minutes.

The average length of stay in hospital was 1.28 days for all patients in the study population. The operative group had an average length of stay of 1.9

days compared with 0.97 days for those patients who did not require an operation. The average number of clinic appointments for the total population was 1.4 (SD, 2.2). The average number of clinic appointments for the operative group was 5.25 compared with 0.50 for the nonoperative group.

DISCUSSION

Analysis of the largest case series of glass punching injuries in the English literature highlights that although this is an uncommon mechanism of injury, the consequences can be severe and debilitating. The typical patient who punches glass is a 26-year-old single male who is unemployed and intoxicated, highlighting that these injuries impact on an already disadvantaged section of our society. Other studies have found

Table 2. Injured Structures

Injured Structure		Volar Injury (%)	Dorsal Injury (%)	Total (%)
Tendons				
Extensors	Extensor digitorum communis		9 (7.2)	9 (7.2)
	Extensor digiti minimi		1 (0.8)	1 (0.8)
	Extensor pollicis longus		3 (2.4)	3 (2.4)
	Extensor pollicis brevis		2 (1.6)	2 (1.6)
	Extensor indicis		1 (0.8)	1 (0.8)
	Extensor carpi radialis		1 (0.8)	1 (0.8)
	Extensor carpi radialis brevis		1 (0.8)	1 (0.8)
	Extensor carpi radialis longus		1 (0.8)	1 (0.8)
	Extensor carpi ulnaris	1 (0.8)		1 (0.8)
	Triceps brachii		1 (0.8)	1 (0.8)
	Abductor pollicis longus		3 (2.4)	3 (2.4)
Total	1 (0.8)	23 (18.4)	24 (19.2)	
Flexors				
Flexors	Flexor carpi ulnaris	5 (4.0)		5 (4.0)
	Flexor carpi radialis	6 (4.8)		6 (4.8)
	Flexor digitorum profundus	3 (2.4)		3 (2.4)
	Flexor digitorum superficialis	4 (3.2)		4 (3.2)
	Flexor pollicis longus	2 (1.6)		2 (1.6)
	Palmaris longus	2 (1.6)		2 (1.6)
Total	22 (17.6)		22 (17.6)	
Muscles				
Muscles	Palmaris longus	5 (4.0)		5 (4.0)
	Flexor carpi ulnaris	2 (1.6)		2 (1.6)
	Flexor digitorum superficialis	3 (2.4)		3 (2.4)
	Flexor pollicis brevis	1 (0.8)		1 (0.8)
	Extensor pollicis brevis		1 (0.8)	1 (0.8)
	Brachioradialis	1 (0.8)	1 (0.8)	2 (1.6)
	Abductor pollicis brevis	1 (0.8)	1 (0.8)	2 (1.6)
	Triceps brachii		2 (1.6)	2 (1.6)
Total	13 (10.4)	5 (4.0)	18 (14.4)	
Vessels				
Arteries	Radial	3 (2.4)		3 (2.4)
	Ulnar	2 (1.6)		2 (1.6)
Total	5 (4.0)		5 (4.0)	
Veins	Axillary	1 (0.8)		1 (0.8)
	Brachial	2 (1.6)		2 (1.6)
Total	3 (2.4)		3 (2.4)	
Nerves				
Nerves	Radial	2 (1.6)	2 (1.6)	4 (3.2)
	Median	4 (3.2)		4 (3.2)
	Ulnar	4 (3.2)		4 (3.2)
Total	10 (8)	2 (1.6)	12 (9.6)	
Bones				
Bones	Little finger metacarpal	1 (0.8)	2 (1.6)	3 (2.4)
	Ring metacarpal		1 (0.73)	1 (0.8)
	Trapezium	1 (0.8)		1 (0.8)
Total	2 (1.6)	3 (2.4)	5 (4.0)	
Total	56 (44.8)	69 (55.2)	125 (100)	

Table 3. The χ^2 Test for Goodness of Fit Measures of Association

Variable	Outcome Association (Injury to)				
	Muscles	Tendons	Nerves	Vessels	Bones
Male	NS	NS	NS	NS	NS
Single	NS	$P < 0.001$	NS	NS	NS
Unemployed	NS	NS	NS	NS	NS
Intoxicated	NS	NS	NS	NS	NS
Intentional	NS	NS	NS	NS	NS
Dominant hand	NS	NS	NS	NS	NS
Volar	NS	NS	NS	NS	NS
Dorsal	NS	NS	NS	NS	NS
Muscle damage	—	NS	$P < 0.001$	$P < 0.031$	$P < 0.042$
Tendon damage	NS	—	$P < 0.001$	$P < 0.001$	NS
Nerve damage	$P < 0.001$	$P < 0.001$	—	$P < 0.001$	NS
Vessel damage	$P < 0.031$	$P < 0.001$	$P < 0.001$	—	NS
Bone damage	$P < 0.042$	NS	NS	NS	—

NS, not significant.

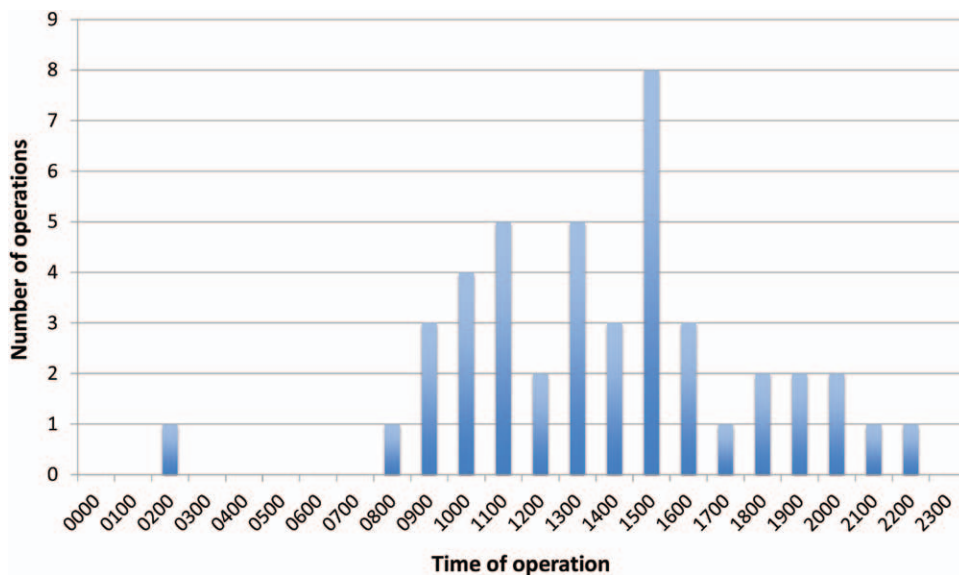


Fig. 2. Time of operation.

a similar demographic pattern.⁴⁻⁶ The dominant hand is more likely to be involved in these injuries, which has obvious functional and socioeconomic consequences.

The superficial location of the tendons, nerves, and vessels in the forearm renders them particularly vulnerable to any penetrating trauma (Fig. 3).^{7,8} Tendons were the most commonly injured structure followed by muscles, nerves, vessels, and bones in descending order, which is a similar injury frequency to other studies.^{9,10} Zone V injuries, which are defined as those occurring between the proximal border of the transverse carpal ligament and the flexor musculotendinous junctions, have been referred to as “spaghetti wrist,” “suicide wrist,” and “full house syndrome” in the literature.^{11,12} These injuries can be devastating in nature, involving as many as 16 different structures, including 12 tendons, 2 arteries, and 2

nerves.¹² The term spaghetti wrist was first defined as 3 completely transected structures (tendon, nerve, or vessel) resulting from a volar wrist laceration.⁸ Fifteen patients in our case series had spaghetti wrist injuries, the worst case involving 8 completely transected structures (6 tendons, 1 artery, and 1 nerve). Not surprisingly, tendon, nerve, and vessel damage were strongly associated with each other in our study population.²

Management

After achieving hemostasis and taking an adequate history (including tetanus status), a thorough clinical examination of the hand, forearm, and arm should be performed. Neurovascular integrity, tendon function, and bony tenderness should be ascertained and documented. A meticulous search for skin lacerations needs to be conducted, while keeping in mind that the size of the wound can be misleading and even

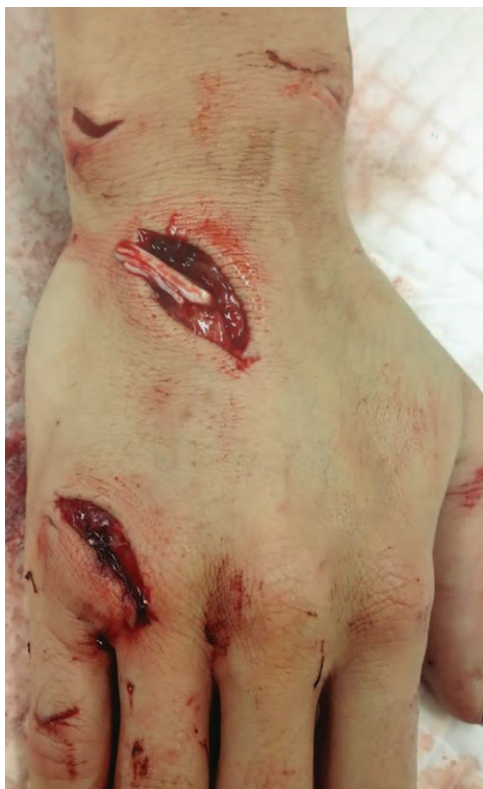

Fig. 3. A patient who presented during the study period with a complete transection of the extensor digitorum communis tendon to the ring finger of the right hand.

small lacerations can have extensive injuries to the deep structures underneath.^{2,8,10} Tuncali et al² examined 226 patients with small lacerations (<2cm for hand and <3cm for forearm) and found that 59% of these patients had an injury to at least 1 deep structure (either tendon, artery, or nerve). Provencher et al⁹ found that the preoperative examination, even when performed by a trained orthopedic hand surgeon, underestimates the extent of the injuries in 94% of patients. Therefore, even after a normal clinical examination, the treating physician should have a low threshold for taking the patient to theatre for formal exploration and repair if required. This is potentially an area of improvement for the studied institution, as 91 of 137 patients with punching glass injuries were discharged home without a formal exploration in theatre. Appropriate imaging of the injured area should also be performed to assess bone integrity and to identify the presence of a retained foreign body.¹³

Economic Burden

The majority of glass-punching injuries tend to present outside of normal working hours (Fig. 1). This is most likely due to the alcohol-fueled nature of these injuries.⁵ This has significant implications for the healthcare system as these injuries put an unne-

cessary burden on the reduced staff numbers which are rostered overnight. Fortunately, the majority of the injuries that required operative management did not need so immediately and could be scheduled on an orthopaedic list during normal working hours the next day (Fig. 2).

A total of 46 operations were required with an average duration of 71 minutes. The operative group had an average length of stay of 1.9 days with 5.25 follow-up clinic appointments compared with an average length of stay of 0.97 days with 0.5 follow-up clinic appointments for the nonoperative group. These figures do not accurately represent the lengthy follow-up required for these injuries because of the limited compliance shown by the majority of patients, which is consistent with other studies.^{5,12} The indirect costs associated with punching glass would also be significant and include factors such as reduced productivity and increased welfare payments because of time off work (either temporary or permanent).

Types of Glass

There are 2 main types of glass found in architectural buildings, annealed glass and safety glass. When sufficient force is applied to annealed glass, it breaks into sharp, jagged fragments, which have the ability to cause serious damage to soft tissue structures.¹⁴ The majority of these injuries occur when the hand is withdrawn from the glass, encountering jagged pieces of glass, which are still retained in the frame. Toughened glass is one type of safety glass and, in comparison with annealed glass of the same thickness, is 4–5 times as strong. In the unlikely event that this glass does break, it shatters into small particles without sharp edges, reducing the risk of injury.¹⁵ Because of the dangerous nature of annealed glass when it is broken, it is not surprising to learn that this type of glass has been responsible for multiple fatalities.^{14,16} In comparison with safety glass, annealed glass is associated with more hospital admissions, more operations, longer follow-up, and more severe injuries to muscles, tendons, nerves, and blood vessels.¹⁴

Prevention

A considerable amount of hospital resources are utilized when a person punches glass, so a focus on prevention is essential to alleviate the burden on our health-care system. Preventing young, intoxicated males from aiming punches at glass is a difficult task, and perhaps the only rational method, although costly, is to replace all glass within arm's reach with safety glass. Many authors support this proposal and suggest that legislation is the only effective means of preventing annealed glass injuries.^{14,17,18} Studies in the United States led to federal legislation enforcing

the use of safety glass in 1977, resulting in the virtual elimination of serious annealed glass injuries in that country.^{14,17} We also support the preventative strategies aimed at reducing alcohol-fuelled violence; however, discussion of public health-orientated alcohol policy is outside the scope of this paper.

Standards Australia is the governing body responsible for glass legislation in Australia. Their most recent guidelines, released in 2006, outline the acceptable use of annealed and safety glass in homes, schools, childcare centers, and aged-care facilities.¹⁹ Although there has been a significant reduction in the acceptability of annealed glass over the years, there are still numerous circumstances in which annealed glass is considered suitable. When the new guidelines are released, we strongly recommend that Standards Australia make their guidelines stricter and prohibit the use of annealed glass. Although we can appreciate the considerable expense associated with this proposed movement, the reduction in health-care costs from glass injuries would be substantial. In addition, it would be ideal to have a governing body that ensures that new buildings, as well as existing buildings, are in alignment with the new legislation when released.

CONCLUSIONS

In closing, we are aware of the inherent limitations of a retrospective study, namely the validity of the study relying heavily on the quality of the documentation. Some variables were not recorded in the patients' medical chart and were, therefore, unable to be included in the analysis. That said, our experience at a regional Australian hospital shows that while glass punching is an uncommon mechanism of injury, it can cause significant morbidity in a young age group and is, therefore, a major public health concern.⁴ Thorough physical examination, appropriate imaging, and operative repair can lead to improved patient outcomes in an already disadvantaged group of our society. It is hoped that studies such as this will expedite the approval of legislation enforcing the use of safety glass in Australia and lead to a reduction in the burden that these injuries have on the individual, as well as our health-care system.

Devlin Elliott, MBChB

Gold Coast University Hospital, Orthopaedics Department
1 Hospital Boulevard
Southport, QLD, Australia 4215
Email: devlin.elliott@health.qld.gov.au

REFERENCES

1. Clark DP, Scott RN, Anderson IW. Hand problems in an accident and emergency department. *J Hand Surg Br.* 1985;10:297–299.
2. Tuncali D, Yavuz N, Terzioglu A, et al. The rate of upper-extremity deep-structure injuries through small penetrating lacerations. *Ann Plast Surg.* 2005;55:146–148.
3. Evans DM. Hand injuries due to glass. *J Hand Surg Br.* 1987;12:284.
4. Irwin LR, Daly JC, James JH, et al. “Through-glass” injuries. *J Hand Surg Br.* 1996;21:788–791.
5. Bokhari AA, Stirrat AN. The consequences of punching glass. *J Hand Surg Br.* 1997;22:202–203.
6. Gokhan S, Altunci YA, Orak M, et al. Hand and wrist injuries caused by glass cuts: accidental or due to sudden anger? *Tr J Emerg Med.* 2011;11:54–58.
7. Noaman HH. Management and functional outcomes of combined injuries of flexor tendons, nerves, and vessels at the wrist. *Microsurgery* 2007;27:536–543.
8. Puckett CL, Meyer VH. Results of treatment of extensive volar wrist lacerations: the spaghetti wrist. *Plast Reconstr Surg.* 1985;75:714–721.
9. Provencher MT, Allen LR, Gladden MJ, et al. The underestimation of a glass injury to the hand. *Am J Orthop (Belle Mead NJ).* 2006;35:91–94.
10. Iconomou TG, Zuker RM, Michelow BJ. Management of major penetrating glass injuries to the upper extremities in children and adolescents. *Microsurgery* 1993;14:91–96.
11. Bircan C, El O, Akalin E, et al. Functional outcome in patients with zone V flexor tendon injuries. *Arch Orthop Trauma Surg.* 2005;125:405–409.
12. Chin G, Weinzeig N, Mead M, et al. “Spaghetti wrist”: management and results. *Plast Reconstr Surg.* 1998;102:96–102.
13. Opel DJ, Lundin DA, Stevenson KL, et al. Glass foreign body in the spinal canal of a child: case report and review of the literature. *Pediatr Emerg Care.* 2004;20:468–472.
14. Maitra A, Han K. Architectural glass injuries: a case for effective prevention. *Arch Emerg Med.* 1989;6:169–171.
15. Kimia AA, Waltzman ML, Shannon MW, et al. Glass table-related injuries in children. *Pediatr Emerg Care.* 2009;25:145–149.
16. Johnston SE, Langley JD, Chalmers DJ. Serious unintentional injuries associated with architectural glass. *N Z Med J.* 1990;103:117–119.
17. White F. Walking through plate glass: a trial of one. *N Engl J Med.* 1991;324:1373.
18. Ousby J, Wilson DH. 1086 consecutive injuries caused by glass. *Injury* 1982;13:427–430.
19. Standards Australia—General Manager Operations. Standardisation Guide 003: Standards and Other Publications [Standards Australia web site]. Available at: http://www.standards.org.au/StandardsDevelopment/Developing_Standards/Documents/SG-003%20Standards%20and%20Other%20Publications.pdf. Accessed January 24, 2013.