

18F-fluorodeoxyglucose positron emission tomography as a window into human dengue pathophysiology

Author

Kalimuddin, S, Xie, W, Watanabe, S, Tham, JY, Sam, H, Chan, KWK, Yap, TS, Totman, JJ, Chacko, AM, Vasudevan, SG, Low, JG

Published

2021

Journal Title

Antiviral Research

Version

Version of Record (VoR)

DOI

[10.1016/j.antiviral.2020.104991](https://doi.org/10.1016/j.antiviral.2020.104991)

Rights statement

© The Author(s) 2021. This is an Open Access article distributed under the terms of the Creative Commons Attribution-NonCommercial-NoDerivs 4.0 International (CC BY-NC-ND 4.0) License, which permits unrestricted, non-commercial use, distribution and reproduction in any medium, providing that the work is properly cited.

Downloaded from

<http://hdl.handle.net/10072/401014>

Griffith Research Online

<https://research-repository.griffith.edu.au>



Short Communication

^{18}F -fluorodeoxyglucose positron emission tomography as a window into human dengue pathophysiology

Shirin Kalimuddin ^{a,b}, Wanying Xie ^c, Satoru Watanabe ^b, Jing Yang Tham ^d, Huizhen Sam ^a,
Kitti Wing Ki Chan ^b, Tiang Siew Yap ^e, John J. Totman ^{e,1}, Ann-Marie Chacko ^d,
Subhash G. Vasudevan ^{b,f,g}, Jenny G. Low ^{a,b,*}

^a Department of Infectious Diseases, Singapore General Hospital, Singapore

^b Programme in Emerging Infectious Diseases, Duke-National University of Singapore (NUS), Medical School, Singapore

^c Department of Nuclear Medicine and Molecular Imaging, Singapore General Hospital, Singapore

^d Laboratory for Translational and Molecular Imaging, Cancer and Stem Cell Biology Programme, Duke-NUS Medical School, Singapore

^e Clinical Imaging Research Centre, NUS Yong Loo Lin School of Medicine, Singapore

^f Department of Microbiology and Immunology, National University of Singapore, Singapore

^g Institute for Glycomics, Griffith University, Gold Coast Campus, Queensland, Australia



ARTICLE INFO

Keywords:

Dengue
Inflammation
Pathogenesis
FDG-PET

ABSTRACT

In mouse models of dengue virus (DENV) infection, ^{18}F -FDG PET is able to sensitively detect tissue-specific sites of inflammation and disease activity, as well as track therapeutic response to anti-DENV agents. However, the use of ^{18}F -FDG PET to study the pathogenesis of inflammation and disease activity in DENV infection in humans, has not been clinically validated. Here we report the ^{18}F -FDG PET imaging results of two patients during the febrile phase of acute DENV infection, paired with serial serum viral load, NS1 and proinflammatory cytokine measurements. Our findings demonstrate that ^{18}F -FDG PET is able to sensitively detect and quantify organ-specific inflammation in the lymph nodes and spleen, in classic acute dengue fever. This raises the potential for ^{18}F -FDG PET to be used as a research tool that may provide further insights into disease pathogenesis.

We previously reported that ^{18}F -FDG PET was able to detect dengue virus (DENV)-associated tissue-specific inflammation and disease activity, as well as sensitively track therapeutic response to anti-DENV agents in mouse models of infection (Chacko et al., 2017). We demonstrated that ^{18}F -FDG uptake was most prominent in the intestines of AG129 mice infected with DENV, and correlated with increased virus load and proinflammatory cytokines, with a significant temporal trend of ^{18}F -FDG uptake over the time course of infection. ^{18}F -FDG PET was also able to clearly differentiate between mice treated with an antiviral agent and those who were treatment-naïve, as well as between lethal and non-lethal infections with a clinical strain of DENV2. Our pre-clinical findings thus raise the potential for molecular imaging techniques such as ^{18}F -FDG PET to be useful as a modality not only in the study of dengue pathophysiology, but also to monitor response in dengue therapeutic trials.

The use of ^{18}F -FDG PET to study the pathogenesis of DENV-associated inflammation and disease activity in humans however, has

not been formally and systematically validated. To date, there have only been two reports in the literature which describe ^{18}F -FDG PET findings in patients with dengue. In both cases however, imaging was performed to investigate a separate clinical etiology with the diagnosis of dengue made coincidentally (Jinguji et al., 2016; Rittmannsberger et al., 2010). In order to address the current knowledge gaps in DENV pathophysiology, and to obtain a visual image of human internal organs during acute dengue fever, we thus designed a research protocol to perform ^{18}F -FDG PET imaging in patients with dengue, both at the time of acute infection and at convalescence 3–4 weeks after recovery (see supplementary material for full methods). In addition, paired serial serum measurement of viral load (viremia), non-structural protein 1 (NS1) and cytokine levels were performed each imaging time-point. Here, we report the findings from the first two patients.

The study was approved by the institutional ethics review committee (Reference No: CIRB 2016/2252) and written informed consent was obtained from both patients prior to enrolment.

* Corresponding author. Department of Infectious Diseases, Singapore General Hospital, Academia Level 3, 20 College Road, 169856, Singapore.

E-mail address: jenny.low@singhealth.com.sg (J.G. Low).

¹ Present affiliation: The Institute of Medical Imaging and Visualisation, Bournemouth University, United Kingdom.

<https://doi.org/10.1016/j.antiviral.2020.104991>

Received 21 October 2020; Received in revised form 25 November 2020; Accepted 30 November 2020

Available online 3 December 2020

0166-3542/© 2020 The Author(s).

Published by Elsevier B.V. This is an open access article under the CC BY-NC-ND license

(<http://creativecommons.org/licenses/by-nc-nd/4.0/>).

1. Patient A

Patient A was a 45-year old female who presented with four days of fever, arthralgia and generalized rash. Apart from well-controlled hypertension, she had no other co-morbidities. Serum dengue NS1 was positive (SD dengue Duo kit, Standard Diagnostics, Inc.) and a fourplex real-time PCR analysis (Low et al., 2014; Johnson et al., 2005) confirmed that the patient was infected with DENV3 (see supplementary material for detailed methods). Dengue IgG performed by ELISA on day 5 of illness was positive (see supplementary material). Throughout the course of illness, the patient remained normotensive with no clinical evidence of vascular leakage, severe thrombocytopenia, or other features suggestive of severe dengue.

^{18}F -FDG PET, paired with non-contrast enhanced magnetic resonance imaging (MRI) for attenuation correction and anatomical localisation, was performed on day 5 of illness (Fig. 1). This showed increased metabolic uptake in multiple nodal sites including the cervical (maximum standardized uptake volume of ^{18}F -FDG [SUV_{max}]: 5.4), axillary (SUV_{max}: 3.9), external iliac (SUV_{max}: 5.9), inguinal and femoral lymph nodes (SUV_{max}: 5.4). Diffuse increased metabolic uptake was also noted in the spleen (SUV_{max}: 4.5). ^{18}F -FDG uptake in the liver was within normal baseline limits and there was no increased metabolic uptake seen in the small or large intestines. Ascites, pleural and pericardial effusions were not visualized. Repeat imaging performed 4 weeks later showed complete metabolic resolution in the lymph nodes and spleen, consistent with disease resolution.

At the time of the first ^{18}F -FDG PET scan on day 5 illness, the patient had quantifiable low level DENV viremia of 1.7×10^5 genome copies/ml. Serum NS1 levels was 21.0 ng/ml. TNF- α level was 24.8 pg/ml, while serum IL-6 levels were below the detection limit of the ELISA assay (<10 pg/ml). As the patient had been enrolled into the study one day prior to undergoing ^{18}F -FDG PET, blood sampling was also performed on day 4 of illness as per protocol - DENV viremia and serum NS1 levels were 1.3×10^6 copies/ml and 82.8 ng/ml respectively. Attempts were made to isolate the DENV by serially diluting the serum and infecting C6/36 cells (*Aedes albopictus* cell line), however no virus was obtained after three rounds of expansion, likely due to the low viremia level (Table 1). At the time of convalescence at week 4, both DENV viremia and serum NS1 levels were undetectable. These results are shown in Table 1. Detailed methods can be found in the supplementary materials.

Table 1

Blood sampling results.

| Day of illness | Scan 1 | | Scan 2 | | Convalescence | |
|--|-----------------------|-----------|-----------------------|-----------------------|---------------|-----------|
| | 4 | 5 | 5 | 5 | 4 | 4 |
| | Patient A | Patient B | Patient A | Patient B | Patient A | Patient B |
| Hematocrit (%) | 40.6 | - | 41.5 | 47.5 | 40.2 | 38.5 |
| Leukocyte count (x 10 ⁹ /L) | 2.99 | - | 2.69 | 2.44 | 6.80 | 4.83 |
| Platelet count (x 10 ⁹ /L) | 252 | - | 235 | 151 | 369 | 244 |
| DENV viremia (genome copies/ml) | 1.3 x 10 ⁶ | - | 1.7 x 10 ⁵ | 1.3 x 10 ⁸ | UD | UD |
| Serum dengue NS1 (ng/ml) | 82.8 | - | 21.0 | 3967.9 | UD | UD |
| Serum TNF- α (pg/ml) | 24.3 | - | 24.8 | UD | 17.0 | UD |
| Serum IL-6 (pg/ml) | UD | - | UD | UD | UD | UD |

DENV - dengue virus; IL-6 - interleukin-6; TNF- α - tumor necrosis factor- α ; UD - undetectable i.e. below limit of level of detection.

2. Patient B

Patient B was an otherwise healthy 33-year old male who presented with five days of fever, myalgia and retro-orbital pain. Serum dengue NS1 was positive (SD dengue Duo kit, Standard Diagnostics, Inc.). Fourplex real-time PCR confirmed that the patient had a DENV2 infection and the dengue IgG at day 5 of illness was positive (see supplementary materials for detailed methods). Similarly Patient B had an uncomplicated course of acute classic dengue fever.

Patient B underwent ^{18}F -FDG PET imaging on day 5 of acute illness, and at convalescence three weeks after recovery. Due to the onset of the COVID-19 pandemic, the study team was no longer able to travel to the ^{18}F -FDG PET/MRI facility located off-site. Hence, the study protocol was amended to pair ^{18}F -FDG PET with unenhanced low dose computed tomography (^{18}F -FDG PET/CT) (Fig. 2). Similar to Patient A, ^{18}F -FDG PET/CT on day 5 showed increase ^{18}F -FDG uptake in the cervical

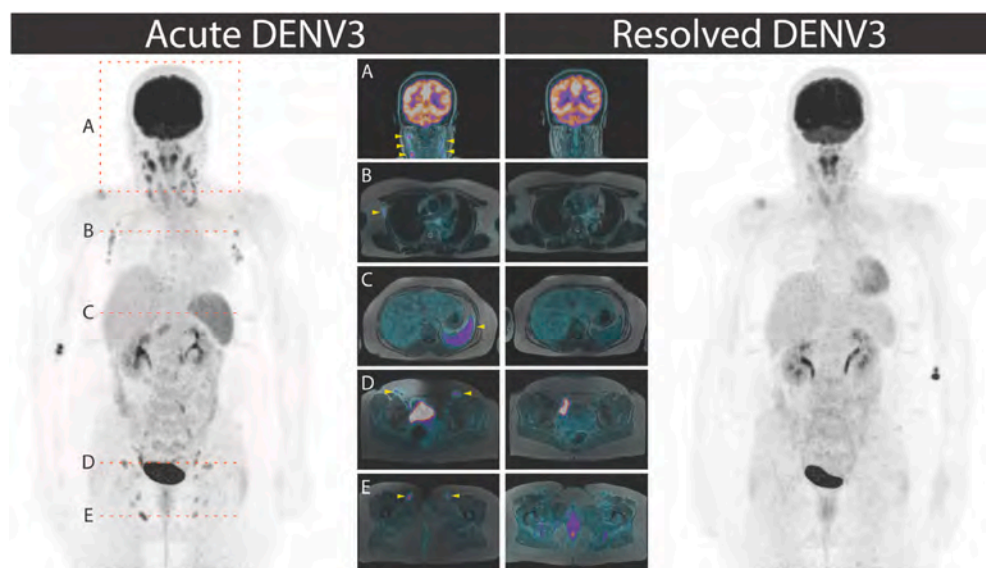


Fig. 1. ^{18}F -FDG PET/MRI images of Patient A at the time of acute (Day 5 illness) and resolved (convalescent) DENV3 infection. The yellow arrows indicate sites of increased ^{18}F -FDG uptake in the cervical (A; maximum standardized uptake volume of ^{18}F -FDG [SUV_{max}]: 5.4), axillary (B; SUV_{max}: 3.9), external iliac (D; SUV_{max}: 5.9), inguinal and femoral lymph nodes (E; SUV_{max}: 5.4) and spleen (C; SUV_{max}: 4.5) during acute infection. Imaging at convalescence shows metabolic resolution of ^{18}F -FDG uptake at these sites. ^{18}F -FDG uptake seen in the brain, liver and urinary system is physiological and within normal expected limits.

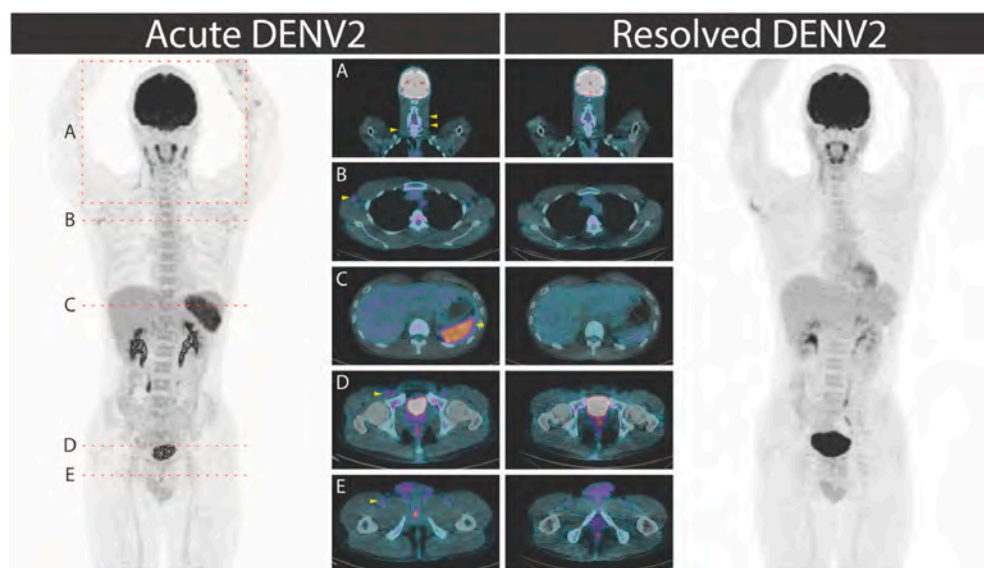


Fig. 2. ^{18}F -FDG PET/CT images of Patient B at the time of acute (Day 5 illness) and resolved (convalescent) DENV2 infection. The yellow arrows indicate sites of increased ^{18}F -FDG uptake in the cervical (A; maximum standardized uptake volume of ^{18}F -FDG [SUV_{max}]: 6.0), axillary (B; SUV_{max} : 3.5), external iliac (D; SUV_{max} : 3.3), inguinal and femoral lymph nodes (E; SUV_{max} : 2.5), and spleen (C; SUV_{max} : 8.5) during acute infection. Imaging at convalescence shows metabolic resolution of ^{18}F -FDG uptake at these sites. ^{18}F -FDG uptake seen in the brain, liver and urinary system is physiological and within normal expected limits.

(SUV_{max} : 6.0), axillary (SUV_{max} : 3.5), external iliac (SUV_{max} : 3.3), inguinal and femoral lymph nodes (SUV_{max} : 2.5), and spleen (SUV_{max} : 8.5). ^{18}F -FDG uptake in the liver was within normal physiological limits, and again there was no evidence of pleural or pericardial effusions, or ascites. Repeat imaging at week 3 during convalescence showed complete metabolic resolution in the lymph nodes and spleen.

At the time of the first scan on day 5 of illness, DENV viremia and serum NS1 levels in Patient B were 1.3×10^8 genome copies/ml and 3967.9 ng/ml respectively. At this level of viremia, the DENV2 virus isolation (see supplementary materials for details) was successful after three rounds of infection/expansion in C6/36 cells. Serum TNF- α and IL-6 levels were below the detection limit of the ELISA assay (<10 pg/ml). During convalescent imaging at week 3, DENV viremia, serum NS1, TNF- α and IL-6 levels were all undetectable. These results are shown in Table 1.

Despite the small sample size, our findings raise the potential for ^{18}F -FDG PET to be used as a safe and non-invasive imaging biomarker to detect and quantify organ-specific inflammation in acute DENV infection. Currently, only clinical serum biomarkers such as dengue viremia and levels of secreted (sNS1) are employed as biomarkers of infection, but both have limitations as endpoints in dengue therapeutic clinical trials (Peeling et al., 2010; Duong et al., 2011). Viral clearance in the blood is affected by both host and viral factors, including but not limited to the host immune status, DENV serotype, as well as infection status i.e. past exposure to a different serotypes (Tricou et al., 2010; Whitehorn et al., 2012; Duyen et al., 2011). Indeed, the discrepancy between viremia and disease outcome has been clearly demonstrated in both mouse models (Watanabe et al., 2015) and human clinical trials, where viremia reduction as a laboratory endpoint has been shown to correlate poorly with clinical response to treatment (Low et al., 2014; Tricou et al., 2010; Nguyen et al., 2013; Tam et al., 2012). Detectable DENV viremia in humans is also short-lived and rapidly declines from peak at onset to undetectable levels within 7 days of illness. Patients are often at the tail-end of the viremic phase by the time they are diagnosed and recruited into clinical trials (Tricou et al., 2011). Levels of sNS1 can also vary widely depending on the infection status, DENV serotype and timing of sampling (Duyen et al., 2011; Tricou et al., 2011). There is thus an urgent need to explore and develop more sensitive and clinically meaningful biomarkers of DENV infection, in order to effectively test potential anti-DENV therapeutics in the clinical trial setting.

In both our patients, ^{18}F -FDG uptake was most prominent in the lymph nodes and spleen, suggesting that inflammation and disease activity were predominantly localised to these organs. Indeed, post-

mortem pathologic examination of patients who died from dengue haemorrhagic fever have demonstrated active viral replication in similar organs (Kularatne et al., 2014; Rathi et al., 2013; Aye et al., 2014). The liver has previously been reported as a site of active viral replication and disease pathology in autopsy examinations of patients who died from severe dengue (Kularatne et al., 2014; Rathi et al., 2013; Aye et al., 2014). However, both our patients did not show any evidence of liver inflammation based on lack of visualisation of increased ^{18}F -FDG uptake. Interestingly, our ^{18}F -FDG PET imaging study in mouse models of DENV infection also did not reveal any increased ^{18}F -FDG uptake in the liver (Chacko et al., 2017). This difference in observation may be due to the high baseline ^{18}F -FDG uptake which normally occurs in the liver, making it less sensitive at detecting small increases in tissue inflammation, particularly in mild disease. It is also plausible that the pathogenesis leading to severe disease and death is different from that seen in mild dengue. However, this will need to be explored further with ^{18}F -FDG PET imaging data from a larger sample size of patients in various stages and severity of illness. (Zompi and Harris, 2012).

Interestingly, our previous mouse study demonstrated increased ^{18}F -FDG uptake in the small intestines but not the lymph nodes and spleen, contrary to the findings in our human subjects. One plausible explanation is that mice in our pre-clinical study had severe lethal DENV infection, and hence differences in sites of ^{18}F -FDG uptake may reflect true differences in pathophysiology between severe and mild dengue. However, it is also increasingly recognized that disease pathogenesis observed in mouse models of DENV infection may not accurately reflect human disease (Zompi and Harris, 2012), and this may also have accounted for the differences observed. Indeed, it is well recognized that the lack of a good *in vivo* pre-clinical infection model is one of the biggest challenges in DENV therapeutic development, and steps to address this gap with human challenge studies are underway (Yan, 2015).

Consistent with established DENV viral and NS1 kinetics, Patient A's DENV and NS1 levels fell rapidly between day 4 and 5 of illness, with a one-log decrease in DENV viremia as measured by quantitative real-time PCR over a 24 h period, and an almost 4-fold decrease in NS1 levels over the same time period. Additionally, both patients had either undetectable or only mildly elevated serum TNF- α and IL-6 levels, consistent with what others have reported (Kumar et al., 2012; Zhao et al., 2016). Nonetheless we were still able to detect significant abnormal metabolic activity in the lymph nodes and spleen. Although we acknowledge that it is not possible to completely differentiate between persistent organ inflammation and disease activity i.e. viral replication, using ^{18}F -FDG PET, our findings are consistent with animal models of DENV infection

where end-organ viral replication and pathology continue to persist despite falling or even undetectable levels of viremia (Chacko et al., 2017; Watanabe et al., 2015). Our findings thus suggest that ^{18}F -FDG PET is able to sensitively and non-invasively detect sites of disease activity, highlighting the potential for this imaging modality to be used to track disease activity in the research setting especially beyond the peak febrile phase of dengue fever when both the viremia and NS1 levels are rapidly declining.

We were unable to determine whether either patient had primary or secondary infections as we did not have blood samples earlier than day 4 of illness. Nonetheless, as both patients had similar disease course with classic acute dengue fever and consistent imaging findings, this study provides new insight into sites of organ inflammation in dengue fever. Although our study was limited by lack of severe cases and lacked serial imaging over more time-points during the course of acute illness, we believe our findings show proof-of-concept that ^{18}F -FDG PET could potentially be a useful research tool to define and quantify organ-specific inflammatory activity in acute DENV infection that may provide further insights into disease pathogenesis. Further exploratory validation studies on the utility of ^{18}F -FDG PET as an imaging modality in other acute viral diseases are also warranted.

Author contributions

SK, JGL, SV and AMC designed the study. SK and SHZ recruited the patients. TSY and JJT supervised the imaging. XWY, TJY, CBLB and AMC analyzed the images. SW and KWKC performed the laboratory analysis. All authors contributed to the writing of the manuscript.

Declaration of competing interest

None.

Acknowledgements

This study was funded by Duke-NUS Medical School and the Estate of Tan Sri Khoo Teck through a Khoo Collaborative Pilot grant, and in part by the National Medical Research Council of Singapore (NMRC grant MOH-000086; MOH-OFIRG18-may-0006). We thank our general practice colleagues for helping identify patients for this study, and the patients who participated.

Appendix A. Supplementary data

Supplementary data to this article can be found online at <https://doi.org/10.1016/j.antiviral.2020.104991>.

References

Aye, K.S., Charngkaew, K., Win, N., Wai, K.Z., Moe, K., Punyadee, N., et al., 2014. Pathologic highlights of dengue hemorrhagic fever in 13 autopsy cases from Myanmar. *Hum. Pathol.* 45 (6), 1221–1233.

- Chacko, A.M., Watanabe, S., Herr, K.J., Kalimuddin, S., Tham, J.Y., Ong, J., et al., 2017. ^{18}F -FDG as an inflammation biomarker for imaging dengue virus infection and treatment response. *JCI insight* 2 (9).
- Duong, V., Ly, S., Lorn Try, P., Tuiskunen, A., Ong, S., Chroeng, N., et al., 2011. Clinical and virological factors influencing the performance of a NS1 antigen-capture assay and potential use as a marker of dengue disease severity. *PLoS Neglected Trop. Dis.* 5 (7), e1244.
- Duyen, H.T., Ngoc, T.V., Ha do, T., Hang, V.T., Kieu, N.T., Young, P.R., et al., 2011. Kinetics of plasma viremia and soluble nonstructural protein 1 concentrations in dengue: differential effects according to serotype and immune status. *J. Infect. Dis.* 203 (9), 1292–1300.
- Jingui, M., Kajiya, Y., Nakajo, M., Nakajo, M., Yoshiura, T., 2016. Increased ^{18}F -FDG uptake in the spleen and multiple lymph nodes in dengue fever. *Clin. Nucl. Med.* 41 (5), e255–e256.
- Johnson, B.W., Russell, B.J., Lanciotti, R.S., 2005. Serotype-specific detection of dengue viruses in a fourplex real-time reverse transcriptase PCR assay. *J. Clin. Microbiol.* 43 (10), 4977–4983.
- Kularatne, S.A., Imbulpitaya, I.V., Abeysekera, R.A., Waduge, R.N., Rajapakse, R.P., Weerakoon, K.G., 2014. Extensive haemorrhagic necrosis of liver is an unpredictable fatal complication in dengue infection: a postmortem study. *BMC Infect. Dis.* 14, 141.
- Kumar, Y., Liang, C., Bo, Z., Rajapakse, J.C., Ooi, E.E., Tannenbaum, S.R., 2012. Serum proteome and cytokine analysis in a longitudinal cohort of adults with primary dengue infection reveals predictive markers of DHF. *PLoS Neglected Trop. Dis.* 6 (11), e1887.
- Low, J.G., Sung, C., Wijaya, L., Wei, Y., Rathore, A.P.S., Watanabe, S., et al., 2014. Efficacy and safety of celgivosir in patients with dengue fever (CELADEN): a phase 1b, randomised, double-blind, placebo-controlled, proof-of-concept trial. *Lancet Infect. Dis.* 14 (8), 706–715.
- Nguyen, N.M., Tran, C.N., Phung, L.K., Duong, K.T., Huynh Hle, A., Farrar, J., et al., 2013. A randomized, double-blind placebo controlled trial of balapiravir, a polymerase inhibitor, in adult dengue patients. *J. Infect. Dis.* 207 (9), 1442–1450.
- Peeling, R.W., Artsob, H., Pelegrino, J.L., Buchy, P., Cardoso, M.J., Devi, S., et al., 2010. Evaluation of diagnostic tests: dengue. *Nat. Rev. Microbiol.* 8 (12 Suppl. 1), S30–S38.
- Rathi, K.R., Arora, M.M., Sahai, K., Tripathi, S., Singh, S.P., Raman, D.K., et al., 2013. Autopsy findings in fatal dengue haemorrhagic fever - 06 Cases. *Med. J. Armed Forces India* 69 (3), 254–259.
- Rittmannsberger, H., Foff, C., Doppler, S., Pichler, R., 2010. [Psychiatric manifestation of a dengue-encephalopathy]. *Wien Klin. Wochenschr.* 122 (Suppl. 3), 87–90.
- Tam, D.T., Ngoc, T.V., Tien, N.T., Kieu, N.T., Thuy, T.T., Thanh, L.T., et al., 2012. Effects of short-course oral corticosteroid therapy in early dengue infection in Vietnamese patients: a randomized, placebo-controlled trial. *Clin. Infect. Dis. : Off Publ. Infect. Dif. Soc. Am.* 55 (9), 1216–1224.
- Tricou, V., Minh, N.N., Van, T.P., Lee, S.J., Farrar, J., Wills, B., et al., 2010. A randomized controlled trial of chloroquine for the treatment of dengue in Vietnamese adults. *PLoS Neglected Trop. Dis.* 4 (8), e785.
- Tricou, V., Minh, N.N., Farrar, J., Tran, H.T., Simmons, C.P., 2011. Kinetics of viremia and NS1 antigenemia are shaped by immune status and virus serotype in adults with dengue. *PLoS Neglected Trop. Dis.* 5 (9), e1309.
- Watanabe, S., Chan, K.W., Wang, J., Rivino, L., Lok, S.M., Vasudevan, S.G., 2015. Dengue virus infection with highly neutralizing levels of cross-reactive antibodies causes acute lethal small intestinal pathology without a high level of viremia in mice. *J. Virol.* 89 (11), 5847–5861.
- Whitehorn, J., Van Vinh Chau, N., Truong, N.T., Tai, L.T., Van Hao, N., Hien, T.T., et al., 2012. Lovastatin for adult patients with dengue: protocol for a randomised controlled trial. *Trials* 13, 203.
- Yan, W., 2015. Challenge accepted: human challenge trials for dengue. *Nat. Med.* 21 (8), 828–830.
- Zhao, L., Huang, X., Hong, W., Qiu, S., Wang, J., Yu, L., et al., 2016. Slow resolution of inflammation in severe adult dengue patients. *BMC Infect. Dis.* 16, 291.
- Zompi, S., Harris, E., 2012. Animal models of dengue virus infection. *Viruses* 4 (1), 62–82.