

Primitive small round cell tumour of the adrenal gland presenting with fever of unknown origin and t(12;22)(q13;q12) cytogenetic finding.

Author

Lam, KY, Lo, CY, Shek, TWH, Ma, ESK, Au, WY, Chan, GCF

Published

2001

Journal Title

Journal of Clinical Pathology

Rights statement

© The Author(s) 2001. The attached file is reproduced here in accordance with the copyright policy of the publisher. For information about this journal please refer to the journal's website or contact the author[s].

Downloaded from

<http://hdl.handle.net/10072/55058>

Link to published version

<http://jcp.bmj.com/content/54/12/966.abstract>

Griffith Research Online

<https://research-repository.griffith.edu.au>

Primitive small round cell tumour of the adrenal gland presenting with fever of unknown origin and t(12;22)(q13;q12) cytogenetic finding

K Y Lam, C Y Lo, T W H Shek, E S K Ma, W Y Au, G C F Chan

Abstract

This report describes a left adrenal tumour in a 16 year old Chinese girl who presented with fever of unknown origin. The histological and ultrastructural features of the adrenal tumour were those of a primitive small round cell tumour with neuroendocrine differentiation. Cytogenetic analysis of cultured tumour cells showed a reciprocal translocation t(12;22)(q13;q12). This is the first example of such a tumour being reported in the adrenal gland. The adrenal tumour was also the cause of the fever, which subsided after the removal of the tumour.

(J Clin Pathol 2001;54:966-970)

Keywords: adrenal; cytogenetic; primitive tumour; pyrexia of unknown origin

Tumours that arise from the adrenal medulla show either neuroendocrine or neural differentiation. These include pheochromocytoma, ganglioneuroma, ganglioneuroblastoma, neuroblastoma, neurilemmoma, malignant peripheral nerve sheath tumour, malignant melanoma, primitive neuroectodermal tumour (PNET), and tumours with mixed differentiation.^{1,2} In this report, we describe a primitive adrenal medulla tumour with unique clinicopathological and cytogenetic features.

Case report

PATIENT

A 16 year old Chinese girl, previously in good health, was admitted because of prolonged intermittent fever. Physical examination was unremarkable. Laboratory studies revealed anaemia (haemoglobin concentration, 78 g/litre), mild leucocytosis (white blood cell count, 11.9×10^9 /litre), and a raised erythrocyte sedimentation rate (> 140 mm/hr). The concentration of C3 was 2700 mg/litre (range, 600-1300) and the C reactive protein concentration was 260 mg/litre (normal, < 10 mg/litre). However, immunoglobulin concentrations were within the normal range. Renal and liver functions were normal except for increased concentrations of alkaline phosphatase (674 U/litre; normal range, 36-117) and γ glutamyl transferase (215 U/litre; normal range, 11-49). Screening for hepatitis virus was negative. Bone marrow aspiration and repeated culturing of blood, urine, and bronchoalveolar lavage showed no evidence of bacterial growth. Screening of blood for malaria, rickettsia, and brucella was negative. There was no clinical or

laboratory evidence of collagen vascular disease. During her hospitalisation, the patient suffered from a high swinging temperature; a maximum temperature of 41°C was recorded. Subsequent abdominal ultrasonography revealed a left suprarenal heterogeneous lesion that was confirmed by computed tomography (CT) and magnetic resonance imaging to be a heterogeneous left adrenal mass with a maximum dimension of 6.2 cm (fig 1). Hormonal investigations (24 hour urinary catecholamine values, serum cortisol, and overnight dexamethasone suppression test) were within the normal ranges. Fine needle aspiration of the adrenal mass was performed under CT scan, and revealed features consistent with a malignant tumour. Total adrenalectomy was performed. There was no definite evidence of invasion into the adjacent soft tissue, enlarged lymph nodes, or distant metastases.

The postoperative recovery was uneventful and the swinging fever that had persisted on and off for more than two months duration subsided immediately after surgery. Standard staging of the disease, including a CT scan of the thorax and bone scintigraphy, did not reveal metastatic disease. Adjuvant local radiotherapy and systemic chemotherapy were administered. However, the patient had lung metastases two years after surgery, which was confirmed by biopsy.

Methods

Fresh tissue samples (1 mm³) of the resected adrenal gland were taken. They were (1) fixed in 2.5% buffered glutaraldehyde and then processed for ultrastructural examination under a transmission electron microscope and (2) put into culture medium for cytogenetic studies. Cytogenetic studies were performed

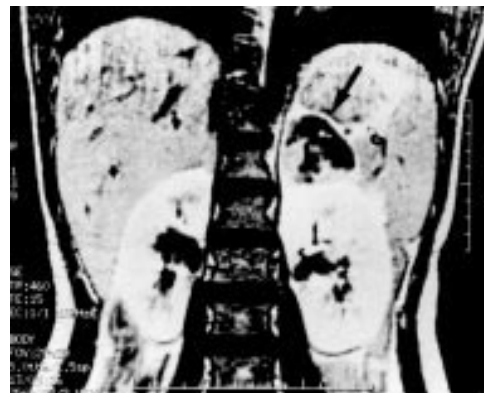

Figure 1 Magnetic resonance imaging scan showing a left adrenal mass (arrow).

Department of
Pathology, University
of Hong Kong, Queen
Mary Hospital,
Pokfulam Road, Hong
Kong, China
K Y Lam
T W H Shek
E S K Ma

Department of
Surgery, University of
Hong Kong
C Y Lo

Department of
Medicine, University
of Hong Kong
W Y Au

Department of
Paediatrics, University
of Hong Kong
G C F Chan

Correspondence to:
Dr Lam, Pathology Division,
School of Medicine, James
Cook University Douglas
Campus, Townsville,
Queensland, QLD 4811,
Australia
akylam@hotmail.com

Accepted for publication
21 May 2001

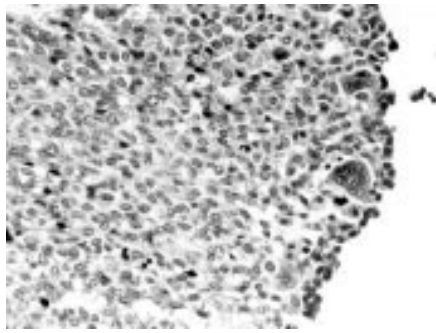


Figure 2 Histological appearance of the adrenal tumour. The tumour is composed of tumour cells with oval nuclei with fine chromatin in a vascular stroma. A few multinucleated tumour giant cells are also present.

on short term overnight synchronised and non-synchronised cultures of marrow cells. These cells were supplemented by a direct harvest and analysed in accordance with standard protocol.³

Fresh frozen tumour tissues were also analysed for the chimaeric transcripts that encode fusion products found commonly in PNET and clear cell sarcoma. These gene fusion products were identified by the reverse transcription polymerase chain reaction (RT-PCR) using cDNA that was derived from tumour tissue RNA as a template. PCR products were identified by gel electrophoresis using ethidium bromide stained gels. The sequence of the primer used and the experimental conditions of the RT-PCR were as described previously.⁴ The presence of amplifiable RNA was confirmed by RT-PCR using primers specific to β actin (a ubiquitously expressed gene in human tissues). Primers specific to the EWS and ATF1 genes were used to test for the presence of the gene fusion transcript commonly found in clear cell sarcoma. The DTC-1A clear cell sarcoma cell line, which produced approximately 950 bp of PCR product, was used as control. Primers specific to EWS, FLI1, or ERG were used to detect the presence of gene fusion transcripts commonly noted in PNET. Two PNET control cell lines known to have a t(11;22) translocation were used as positive controls in these studies. The PCR products were Southern blotted on to a nylon membrane and probed with an internal end labelled oligonucleotide specific to EWS, FLI1, and ERG.

Immunohistochemistry was conducted on 5 μ m thick sections from representative paraffin wax embedded blocks using the avidin-biotin-peroxide complex method.⁵ Antibodies to the following antigens were used: vimentin, neurone specific enolase (NSE), synaptophysin, chromogranin, desmin, smooth muscle actin, myoglobin, myosin, leucocyte common antigen (LCA), Mak-6, CAM 5.2, cytokeratin 7, cytokeratin 20, HMB-45, CD34, and CD99.

Results

GROSS PATHOLOGY

The resected left adrenal gland weighed 180 g. The contour of the adrenal gland was distorted by a medullary tumour measuring

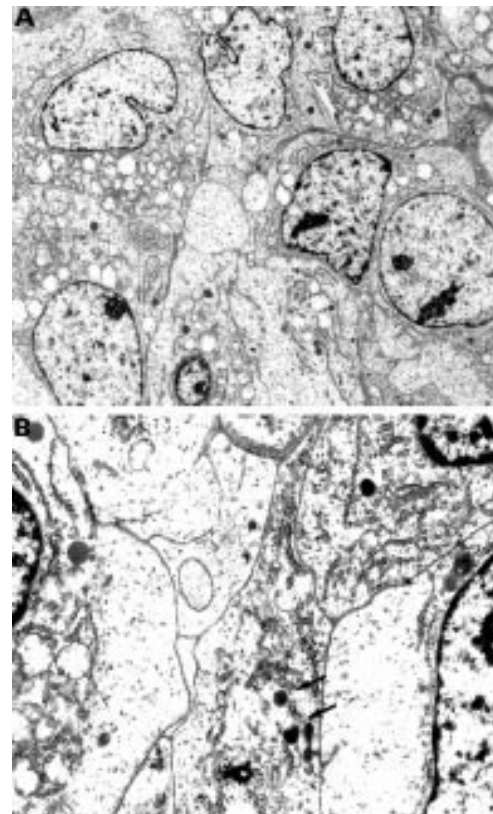


Figure 3 Electron micrograph of the tumour cells (A) Primitive cuboidal cells showing focal "neuritic" processes. (B) Higher magnification of these cells showing their cytoplasm contains numerous mitochondria and ribosomes, in addition to scattered neurosecretory granules (arrows).

8 \times 7.5 \times 4.0 cm. The cut surface of the mass showed white fleshy tumour tissue with multiple areas of haemorrhage and necrosis virtually replacing the whole adrenal gland.

HISTOLOGICAL FEATURES

The adrenal tumour was composed of sheets of uniform small and medium oval cells with scanty cytoplasm and irregular nuclei with fine chromatin (fig 2). Mitotic counts were approximately 1/10 high power fields. In some foci, multinucleated tumour giant cells were noted. Rosettes or rosette-like structures were not present. The tumour cells were embedded in a vascular stroma in which haemorrhage and hemosiderin deposits were frequently found. Extensive areas of necrosis with perivascular preservation of viable tumour cells forming a peritheliomatous pattern were also seen.

IMMUNOHISTOCHEMICAL FINDINGS

Immunohistochemical studies revealed that the primary tumour cells were positive for vimentin but negative for CD99, neuroendocrine markers (NSE, chromogranin, and synaptophysin), cytokeratins (Mak-6, CAM 5.2, cytokeratin 7, and cytokeratin 20), S-100, HMB-45, muscle markers (actin, desmin, myosin, and myoglobin), CD31, CD34, and LCA. The tumour cells from the metastatic lesion in the lung were positive for CD99.

ELECTRON MICROSCOPY

Ultrastructural examination showed closely opposed cells that were uniform and primitive

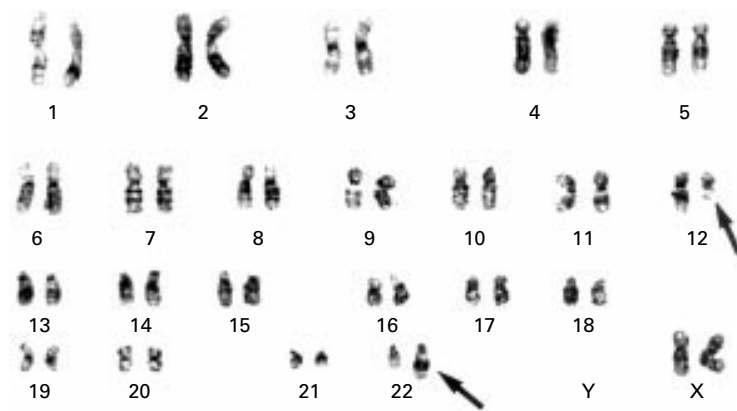


Figure 4 A representative karyotype of the adrenal tumour performed by G-banding with trypsin-Giemsa. The following chromosomal complement is noted: 46, XX t(12;22)(q13;q12) (arrows).

(fig 3). The nuclei showed evenly dispersed chromatin with occasional nucleoli. The tumour cells had elongated cellular processes that interdigitated with each other. Basement membrane material was lacking and desmosomes were absent. Some tumour cells showed a few dense core granules of variable size. No myofibrils, microtubules, or melanosomes were detected.

CYTOGENETICS

Chromosomal analysis of cultured tumour cells revealed translocation between the long arms of chromosome 12 and 22; t(12;22)(q13;q12) (fig 4). On RT-PCR analysis, the tumour was negative for fusion transcripts for PNET or clear cell sarcoma. The absence of the transcripts was confirmed on labelling of Southern blotted PCR products with a cDNA probe.

DIAGNOSIS

The diagnosis of a primitive small round cell tumour of the adrenal gland with neuroendocrine differentiation was corroborated by morphological, immunohistochemical, ultrastructural, and cytogenetic findings. The features were in keeping with PNET.

Discussion

The fever pattern of our patient fulfils the criteria for paraneoplastic fever. Paraneoplastic fever has been defined as unexplained fever that coincides with tumour growth and disappears promptly on tumour removal or control.⁶ Lymphomas (especially Hodgkin's disease) and renal cell carcinomas are the prototypes of tumours frequently associated with paraneoplastic fever.⁶ However, descriptions in the literature of adrenal tumours presenting with prolonged fever as the principle symptom are rare, although there have been some patients with adrenal tumours presenting with neoplastic fever.⁷ These included pheochromocytomas, adrenal cortical carcinomas, and one patient with aldosteronoma.⁷⁻⁹ In our study, an adrenal small round cell tumour was described in which fever was the primary manifestation. The extensive tumour necrosis may have triggered the release of circulating cytokines that mediated the fever. On the basis of this

report, it seems logical that adrenal tumour should be included in the differential diagnosis in patients with fever of undetermined origin.

Abe *et al* described a small round cell variant of malignant peripheral nerve sheath tumours in five patients with tumours located within the soft tissue of the trunks and limbs.¹⁰ The tumours consisted mainly of uniform, small, round tumour cells with scanty cytoplasm. They stained negative for CD99 and tumour rosettes were seen. These features are similar to those noted in our patient. However, there were histological and ultrastructural features that distinguished small round cell variant of malignant peripheral nerve sheath tumour from that of our present patient. In the cases described by Abe *et al*, foci of uniform, short, spindle shaped tumour cells arranged in a whorl-like pattern were seen.¹⁰ Ultrastructural examination also revealed a poorly developed basal lamina that was fragmentous and discontinuous along the cell bodies. Dense core granules were absent in all except one case.

The cytogenetic abnormality found in our patient was t(12;22)(q13;q12). This translocation has never been reported in PNET. t(12;22)(q13;q12) has been reported to involve the fusion of the EWS and ATF1 genes.¹¹ EWS-ATF1 fusion has often been found in clear cell sarcoma but it is not present in conventional cutaneous melanoma.¹² The clinical presentation and pathological, immunohistochemical, and ultrastructural characteristics of the adrenal tumour reported here (such as the absence of reactivity to HMB-45 or melanosomes) excluded the diagnosis of clear cell sarcoma. In addition, RT-PCR studies showed that t(12;22) translocation in the adrenal tumour did not involve EWS-ATF1 fusion, as seen in clear cell sarcoma. Thus, the adrenal tumour had unique pathological and cytogenetic features and was neither characteristic of PNET nor clear cell sarcoma on cytogenetic investigation.

The authors thank Dr P Sorenson, Department of Pathology, British Columbia's Children Hospital, Vancouver, BC, Canada for his help with the RT-PCR analysis.

- Lam KY. The pathology of adrenal tumours. *Cancer Journal* 1994;7:181-7.
- Marina NM, Etcubanas E, Parham DM, *et al*. Peripheral primitive neuroectodermal tumour (peripheral neuroepithelioma) in children: a review of the St Jude experience and controversies in diagnosis and management. *Cancer* 1984;64:1952-60.
- Chan CL, Ha SY, Ching LM, *et al*. Cytogenetic and immunophenotypes of childhood acute lymphoblastic leukaemia in Hong Kong. *Cancer Genet Cytogenet* 1994;76:118-24.
- Zucman J, Delattre O, Desmaze C, *et al*. EWS and ATF-1 gene fusion induced by t(12;22) translocation in malignant melanoma of soft parts. *Nat Genet* 1993;4:341-5.
- Hsu SM, Raine L, Franger H. Use of avidin-biotin-peroxidase complex (ABC) in immunoperoxidase techniques: a comparison between ABC and unlabelled antibody (PAP) procedures. *J Histochem Cytochem* 1981;29:577-80.
- Johnson M. Neoplastic fever. *Palliat Med* 1996;10:217-24.
- Klausner JM, Nakash R, Inbar M, *et al*. Prolonged fever as a presenting symptom in adrenal tumours. *Oncology* 1988;45:15-17.
- Fukumoto S, Matsumoto T, Harada SI, *et al*. Pheochromocytoma with pyrexia and marked inflammatory signs: a paraneoplastic syndrome with possible relation to interleukin-6 production. *J Clin Endocrinol Metab* 1991;73:877-81.
- Weiss M, Margolis J, Zinn HJ, *et al*. Necrotising adenocarcinoma of the adrenal as a cause of prolonged pyrexia. *J Am Geriatr Soc* 1970;18:428-30.
- Abe S, Imamura T, Park P, *et al*. Small round-cell type of malignant peripheral nerve sheath tumour. *Mod Pathol* 1998;11:747-53.

- 11 Gill S, McManus AP, Crew AJ, *et al.* Fusion of the EWS gene to a DNA segment from 9q22-31 in a human myxoid chondrosarcoma. *Genes Chromosomes Cancer* 1995;12:307-10.
- 12 Langezaal SM, Graadt van Roggen JF, Cleton-Jansen AM, *et al.* Malignant melanoma is genetically distinct from clear cell sarcoma of tendons and aponeurosis (malignant melanoma of soft parts). *Br J Cancer* 2001;84:535-8.

7th European Forum on Quality Improvement in Health Care

21-23 March 2002

Edinburgh, Scotland

We are delighted to announce this forthcoming conference in Edinburgh. Authors are invited to submit papers (call for papers closes on **Friday 5 October 2001**) and delegate enquiries are welcome.

The themes of the Forum are:

- Leadership, culture change, and change management
- Achieving radical improvement by redesigning care
- Health policy for lasting improvement in health care systems
- Patient safety
- Measurement for improvement, learning, and accountability
- Partnership with patients
- Professional quality: the foundation for improvement
- Continuous improvement in education and training
- People and improvement.

Presented to you by the BMJ Publishing Group (London, UK) and Institute for Healthcare Improvement (Boston, USA). For more information contact: quality@bma.org.uk or look at the website www.quality.bmjpg.com. Tel: +44 (0)20 7383 6409; fax: +44 (0)20 7373 6869.