

Evaluation, diagnosis and management of chronic urticaria

Author

Perera, Eshini, Sinclair, Rodney

Published

2014

Journal Title

Australian Family Physician

Rights statement

© 2014 Australian Family Physician. Reproduced with permission. Permission to reproduce must be sought from the publisher, The Royal Australian College of General Practitioners.

Downloaded from

<http://hdl.handle.net/10072/67594>

Link to published version

<http://www.racgp.org.au/afp/2014/september/evaluation,-diagnosis-and-management-of-chronic-urticaria/>

Griffith Research Online

<https://research-repository.griffith.edu.au>



Eshini Perera
Rodney Sinclair

Evaluation, diagnosis and management of chronic urticaria

Background

Urticaria produces weals, which are itchy and can affect the quality of life and social functioning of an affected patient. There are several different subtypes of urticaria. This article focuses on chronic urticaria.

Objective

This article details the approach to assessment and management of chronic urticaria.

Discussion

Chronic urticaria is characterised by the occurrence of weals, which occur on a daily basis for more than 6 weeks. Clinical history and physical examination alone are sufficient to establish a diagnosis. Non-sedating histamine H₁ receptor antagonists are the first-line treatment and are effective in 60% of patients. These may be supplemented with histamine H₂ receptor antagonists. The use of second- and third-line treatments is also discussed.

Keywords

urticaria; diagnosis; general practice

6 weeks.³ Some consider urticarial vasculitis to be a chronic urticaria; however, the term chronic urticaria commonly refers to an ordinary urticaria. Chronic urticaria can have a negative impact on a patient's quality of life, affecting social function and emotional wellbeing.²

Evaluation and diagnosis of chronic urticaria

History

A detailed history is usually sufficient to establish a diagnosis of urticaria and the type of urticaria. Chronic urticaria persists for more than 6 weeks. An urticaria that lasts less than 6 weeks is an acute urticaria in which the characteristic weals may last less than 24 hours. If a patient describes a history of individual lesions lasting more than 24 hours, then vasculitic urticaria should be considered. For patients who are unable to estimate the time frame of the lesion, drawing around a new lesion and then recording how long this takes to disappear can be useful.

Patients report weals that are associated with itch, often worse at night. This pruritus can be debilitating enough to affect activities of daily living and quality of life. For patients who have difficulty describing symptoms (eg after the symptoms have resolved), it is often useful to show patients photographs of urticarial lesions. *Table 1* outlines a number of history questions that may be relevant.

Medication history is particularly important. Urticaria can be caused by a number of medications including non-steroidal anti-inflammatory drugs (NSAIDs), opioids, antibiotics, antidepressants, antihypertensives, antifungals, angiotensin converting enzyme (ACE) inhibitors and cyclooxygenase (COX)-2 inhibitors.

Urticaria is characterised by swelling of the skin and mucosa due to plasma leakage.¹

The term is often used to describe a rash that may present with weals, with or without angioedema. Urticaria can be divided into a number of subgroups listed below:

- ordinary urticaria
 - acute urticaria
 - chronic urticaria
- urticarial vasculitis
- physical urticaria.

These subgroups are differentiated by the time frame, clinical presentation and triggers of the urticarial rash (*Figure 1*).² The focus of this article is on chronic urticaria, which is a chronic relapsing skin disease characterised by highly pruritic weals that persist for less than 24 hours and recur on a daily basis for more than

Urticaria can appear many months to years after starting the medications.

In 80–90% of cases no identifying trigger for chronic urticaria can be established.⁴ However, it is thought that many of these idiopathic urticarias may be attributed to autoimmune causes. Chronic urticaria is associated with autoimmune disorders, most commonly hypothyroidism, but also coeliac disease, systemic lupus erythematosus (SLE) and type 1 diabetes mellitus.^{5,6} History taking could also focus on excluding these diseases. Patients with autoimmune chronic urticaria have been found to have a more aggressive disease course and are resistant to treatment.⁷ There are some less clear associations between chronic urticaria and malignancy. Urticular vasculitis is, however,

associated with malignancy.^{8,9} Associations of chronic urticaria with *Helicobacter pylori* and *Candida* infections are not well substantiated.¹⁰

Physical assessment

Urticaria presents as pink or white well-circumscribed, raised weals surrounded by an erythematous base and central pallor. These weals may become confluent, forming large plaques. Urticular lesions may vary in size and shape, ranging from annular to serpiginous outlines, and ranging from lesions that are millimetres to a few centimetres in size. Morphology of these weals may help distinguish between physical urticarias and other subgroups of urticaria. Weals may be accompanied by angioedema, which is non-pitting

asymmetric swelling that may affect the lips, cheeks, limbs, genitals and periorbital area.

Differential diagnoses to consider

There are a number of underlying diseases that may present with urticaria. Consider SLE, where fever, weight loss and arthritis occur concurrently. Cryopyrin-associated periodic syndromes (eg Muckle-Wells syndrome) are genetic inflammatory diseases that may present characteristically with periodic urticaria, fever, conjunctivitis and muscle and skin sensitivity. They may also be associated with sensorineural hearing loss and arthritis.¹¹ Conditions that may present with skin eruptions that mimic urticaria are outlined in Table 2. The

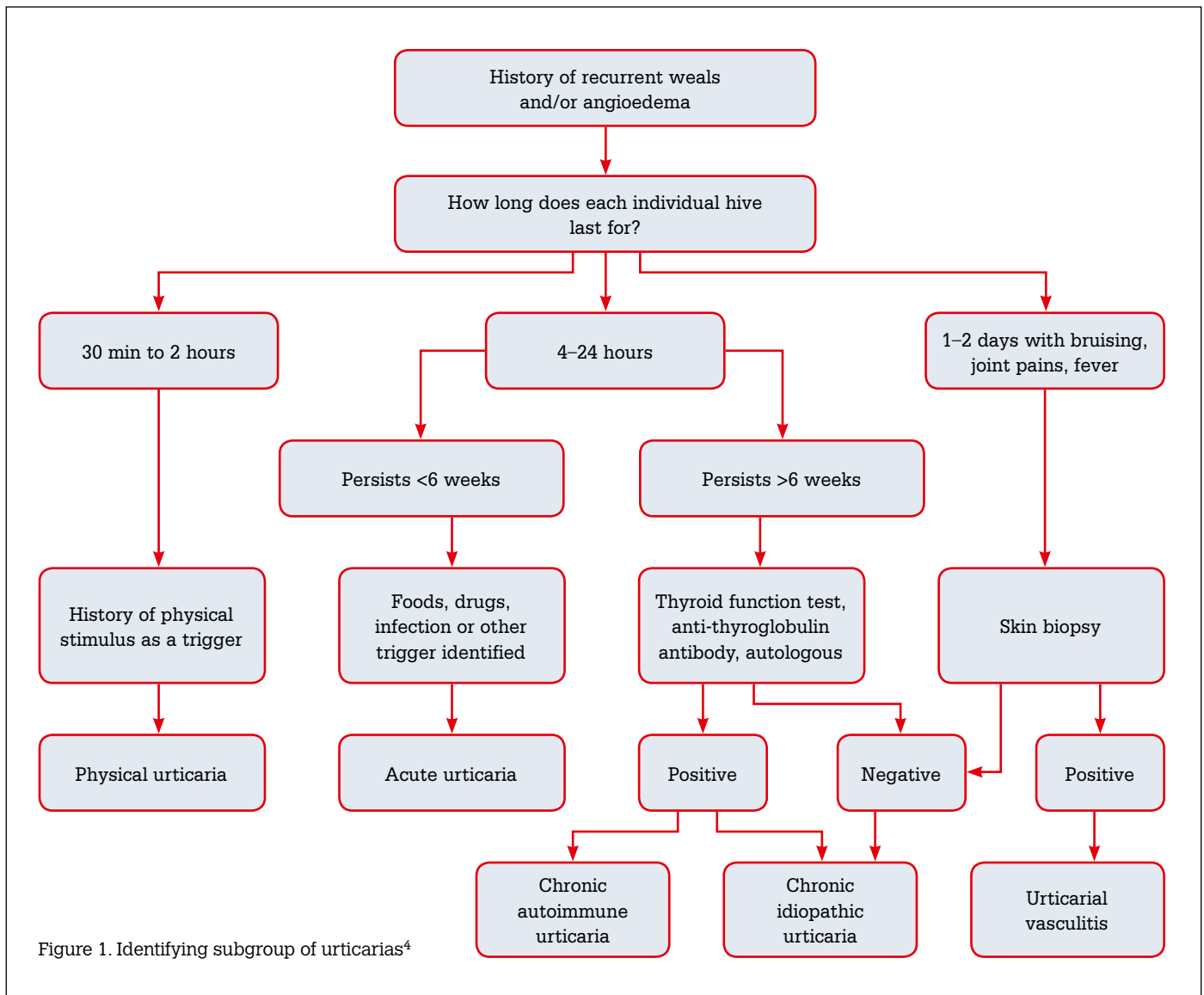


Figure 1. Identifying subgroup of urticarias⁴

clinical history and physical examination findings may provide clues to these differentials. A skin biopsy can be performed if the diagnosis is in question.

Investigations

Normally, laboratory investigations are not required in the diagnosis of chronic urticaria and most investigations will be normal. A list of suggested investigations to rule out other differential diagnoses is shown in *Table 3*.

Autologous serum skin test

At present, an autologous serum skin test (ASST) is the most useful test for investigating chronic urticaria and has a reported 81% sensitivity and 78% specificity.¹² Currently, this test can only be performed by specialists. It is used to determine whether a patient may have a good response to immunomodulatory treatments.¹³

The procedure involves drawing a sample of blood from the patient during a flare. The blood is then separated by centrifugation to form serum. A small amount of the serum is then injected into unaffected skin on the forearm. At the same time equal amounts of normal saline and histamine are injected on the same forearm. The response at 30 minutes is then recorded. A weal of >1.5 mm at the site where the serum was injected is considered a positive response. A weal larger than the saline-induced response is also considered positive. Poor injecting techniques and administration in dermographic patients may elicit a false-positive result. The ASST has a role in determining the prognosis of a patient with chronic urticaria. A positive ASST test also correlates with the duration of the disease and the severity of the urticaria.¹³

Role of skin prick testing

Skin prick testing (SPT) is a procedure where a small sample of allergen is introduced into the patient's skin by pricking the skin, to induce an allergic response. SPT is not usually indicated in patients with chronic urticaria, as a positive finding is not always clinically useful. A study examining 88 patients with food and aero-allergies found that, of the patients with positive SPT for food allergens, only 34.6% had clinically relevant food-induced urticaria.¹⁴ Furthermore, another study by the same author examined 172

patients for house dust mite allergies and found that 34.9% of patients with chronic urticaria had a positive test but this was only relevant in 3.3% of cases.⁴

Skin biopsy

Skin biopsies are not usually performed in chronic urticaria. However, if the diagnosis is in question, particularly if there is suspicion of urticarial

vasculitis, then a biopsy can be performed. *Table 4* outlines the indications for a skin biopsy.

Treatment

Patients should be educated on avoiding trigger factors and aggravating factors. The natural history and progression of the disease should also be discussed. Avoidance of NSAIDs and ACE inhibitors should be encouraged. Non-medicated

Table 1. History questions

| |
|--|
| <p>1. Signs and symptoms associated with lesion</p> <ul style="list-style-type: none"> • Pruritis/burning sensation • Duration of individual lesions • Length of time that ongoing lesions have been occurring • Accompanying angioedema • Associated systemic signs and symptoms including fever, weight loss, joint pain, abdominal pain.* |
| <p>2. Identifying triggers</p> <ul style="list-style-type: none"> • Newly administered drugs <ul style="list-style-type: none"> • Antibiotics • Non-steroidal anti-inflammatory drugs (NSAIDs) • Hormones |
| <p>3. Aggravating factors</p> <ul style="list-style-type: none"> • Physical stimuli[†] (eg heat/tight clothing, cold/heat) • Alcohol • Stress • Food (food allergies are a rare cause of chronic urticaria; however, some foods, for example spicy foods, aggravate symptoms.) |
| <p>4. Atopy</p> |
| <p>5. Past medical history and changes to health</p> |
| <p>*To exclude differential diagnosis [†]If physical factors are the main trigger then consider a diagnosis of physical urticarial syndrome.</p> |

Table 2. Conditions that may mimic chronic urticaria

| Disease | When to consider the diagnosis |
|--|---|
| Urticarial vasculitis | <ul style="list-style-type: none"> • Hives are painful (not pruritic) • Hives last more than 48 hours • Residual bruising or pigmentation occurs after resolution of hives • May have symptoms like fever, chills, arthralgias • May have previously had another systemic inflammatory disease |
| Cryoglobulinemia | <ul style="list-style-type: none"> • Lesions over buttocks and lower extremities. • May occur in patients with hepatitis B/C |
| Mastocytosis | <ul style="list-style-type: none"> • Lesions occur with very mild physical trauma, for example light touch |
| Polymorphic eruption of pregnancy | <ul style="list-style-type: none"> • Occur in pregnant patients • Presents within abdominal striae • Does not affect periumbilical area • Sparing of face, palms, soles |

lotions such as menthol in aqueous cream can alleviate symptoms.

First-line therapy

Histamine H₁ receptor antagonists

Histamine H₁ receptor antagonists have been shown to reduce symptoms of hives and pruritus. These agents should be taken once daily. Not all patients will respond completely to H₁ receptor antagonists. About 60% of patients with chronic urticaria respond to H₁ receptor antagonists.¹⁵ If the patient fails to respond then another H₁ receptor antagonist can be trialled. H₁ receptor antagonist doses should be maximised before trialling other therapies.

First-generation H₁ receptor antagonists, including hydroxyzine, diphenhydramine and cyproheptadine, can cause anticholinergic side effects and sedation. These side effects make the first-generation H₁ receptor antagonists useful for patients who have insomnia secondary to pruritus. Second-generation H₁ receptor antagonists,

including cetirizine, loratadine, levocetirizine and desloratadine are equally effective and do not have the sedative and anticholinergic effects. For this reason they are the mainstay of treatment.

Histamine H₂ receptor antagonists

Histamine H₂ receptor antagonists, including cimetidine, ranitidine and nizatidine, can be used in conjunction with H₁ receptor antagonists. They are not generally used alone.

Second-line therapy

Corticosteroids

Short-term use of corticosteroids is reserved for symptoms that are severe and cause significant pain and distress. Complete resolution of symptoms occurs very quickly. The use of corticosteroids is controversial because patients often have relapses after cessation of corticosteroids. Long-term use is not indicated because of the side effects of hypertension, hyperglycaemia, weight gain, osteoporosis and peptic ulcers.

Doxepin

Doxepin is a tricyclic antidepressant with potent H₁ and H₂ receptor antagonist activity.¹⁵ It is used at a doses of 10–30 mg/day for chronic urticaria; however, dosage can be increased if patients are treated concurrently for depression. Doxepin can cause sedation and is usually taken at night. Doxepin is subsidised through the Pharmaceutical Benefits Scheme (PBS) and may be the only affordable option for healthcare card holders. Mirtazepine, another antidepressant, has been shown to reduce symptoms of pruritus because of its effects on the histamine H₁ receptors.

Narrowband ultraviolet B light

Narrowband ultraviolet B (NB-UVB) is used in a variety of skin ailments because of its anti-inflammatory and immunosuppressive properties. NB-UVB may be useful in patients with chronic urticaria. In an unblinded study examining 81 patients, 33 control patients were given H₁ receptor antagonists and 48 patients were treated with NB-UVB and H₁ receptor antagonists.¹⁶ Urticarial symptoms were reduced in both groups but the urticarial activity was significantly lower in the NB-UVB/H₁ receptor antagonist group.

Third-line therapy

Cyclosporine

There are numerous reports in the literature detailing the efficacy of cyclosporine. One study showed that more than one-third of patients stayed in remission after cessation of cyclosporine and a further one-third had only a mild relapse.¹⁷ Side effects include hypertension and renal toxicity. Patients with chronic urticaria require a private prescription.

Other medications

There is evidence that medications including dapsone, intravenous immunoglobulin and methotrexate are useful treatments for chronic urticaria; however, only uncontrolled case studies have been published.

Emerging therapies

Omalizumab

Omalizumab is an anti-IgE monoclonal antibody, which has been shown to be beneficial in the treatment of chronic urticaria. Its main mechanism

Table 3. Suggested investigations

| Test | Findings |
|--|---|
| FBE | <ul style="list-style-type: none"> Usually normal in chronic urticaria If there is eosinophilia – further investigation for atopic disorder or parasites should be performed. |
| CRP/ ESR | <ul style="list-style-type: none"> Usually normal in chronic urticaria May have mild elevation of ESR If there is a significant elevation in either CRP/ESR then consider investigation for systemic diseases/urticarial vasculitis. Further tests include cryoglobulins, hepatitis B/C serology, liver function tests |
| Thyroid function tests and thyroid antibodies | <ul style="list-style-type: none"> perform in patients who are unresponsive to antihistamines |
| ANA | <ul style="list-style-type: none"> Can be raised in patients with autoimmune diseases. |
| ANA, antinuclear antibodies; CRP, C-reactive protein; ESR, erythrocyte sedimentation rate; FBE, full blood examination | |

Table 4. Indications for a skin biopsy

| |
|---|
| <ul style="list-style-type: none"> Lesions occurring for more than 24 hours Painful urticarial lesions Petechia or purpural lesions associated with urticaria Elevated CRP/ESR Systemic symptoms Unresponsive to antihistamines. Features of mastocytosis (flushing, diarrhoea, syncope, abdominal cramping) |
|---|

of action is by reducing free IgE levels. A number of phase III trials have been published showing its superior results when compared with H₁ receptor antagonists.^{18,19} A recent phase III, multicentre, randomised, double-blind, placebo-controlled study examined the use of omalizumab in 336 patients.²⁰ Patients received either 300 mg subcutaneous omalizumab (n = 252) or placebo (n = 84). After 12 weeks there were significant improvements in pruritus, number of hives, size of hives and days without angioedema.²⁰ However, after cessation of omalizumab symptoms reoccurred.

Autologous serum and autologous whole blood therapy

Autologous serum is a promising treatment, which has been shown to be useful in the treatment of severe urticaria. As with the process of ASST, the patient's blood is collected and centrifuged to produce a serum. This serum is then injected intramuscularly every fortnight for 8 weeks. Results have been particularly promising for patients who are ASST-positive.

Similarly, the efficacy of autologous whole blood (AWB) injections has been described in the literature.²¹ One placebo-controlled trial examining 56 patients showed that AWB treatment improved the number, size and duration of symptoms in patients with chronic urticaria who were ASST-positive.²¹

A recent study by Kocaturk et al²² showed conflicting evidence suggesting that AWB and autologous serum injections had no superiority over a placebo in a study consisting of 88 patients with chronic urticaria.

Key points

- Diagnosis of chronic urticaria can be established with a history and physical examination.
- An alternative diagnosis should be considered in the context of accompanying symptoms.
- Histamine H₁ receptor antagonists are the mainstay of treatment.
- Patients who are unresponsive to treatments should be referred to a specialist for alternative treatment options.

Authors

Eshini Perera MBBS, BMedSci, MMed, GP registrar and Master of Public Health candidate, Medicine,

Dentistry and Health Sciences, Melbourne University, Parkville, VIC. eshinip@gmail.com

Rodney Sinclair MBBS, MD, FACD, Professor of Dermatology, University of Melbourne, and Director of Dermatology, Epworth Hospital, Melbourne, VIC

Competing interests: Rodney Sinclair received payment from Novartis for travel, accommodation and meeting expenses relating to attendance at an overseas meeting on urticaria.

Provenance and peer review: Not commissioned, externally peer reviewed.

References

1. Grattan CE, Kobza Black A. Urticaria and Mastocytosis. In: Burns T, Breathnach S, Cox N, Griffiths C, editors. *Rook's Textbook of Dermatology*, Volume 1. 8th edn. West Sussex: Blackwell Publishing, 2010;22.1–22.36.
2. Staubach P, Eckhardt-Henn A, Dechene M, et al. Quality of life in patients with chronic urticaria is differentially impaired and determined by psychiatric comorbidity. *Br J Dermatol* 2006;154:294–98.
3. Kaplan A, Greaves M. Pathogenesis of chronic urticaria. *Clin Exp Allergy* 2009;39:777–87.
4. Wolff K, Johnson R, Suurmond R. *Fitzpatrick's Color Atlas and Synopsis of Clinical Dermatology*. 5th edn. New York, McGraw-Hill, 2005.
5. Kulthanan K, Wachirakaphan C. Prevalence and clinical characteristics of chronic urticaria and positive skin prick testing to mites. *Acta Derm Venereol* 2008;88:584–88.
6. Goh CL, Tan KT. Chronic autoimmune urticaria: where we stand? *Indian J Dermatol* 2009;54:269–74.
7. Confino-Cohen R, Chodick G, Shalev V, Leshno M, Kimhi O, Goldberg A. Chronic urticaria and autoimmunity: associations found in a large population study. *J Allergy Clin Immunol* 2012;129:1307–13.
8. Sabroe R, Seed P, Francis D, Barr R, Black A, Greaves M. Chronic idiopathic urticaria: comparison of the clinical features of patients with and without anti-IgE or anti-IgG autoantibodies. *J Am Acad Dermatol* 1999;40:443–50.
9. Zhang Y, Morita E, Matsuo H, Ueda D, Dekio S. Urticarial erythema associated with IgA myeloma. *J Dermatol* 2004;31:661.
10. Calvo-Romero J. Diffuse large B cell lymphoma in a patient with hypocomplementemic urticarial vasculitis. *J Postgrad Med* 2003;49:252.
11. Moriera A, Rodrigues J, Delgado L, Fonseca J, Vaz M. Is *Helicobacter pylori* infection associated with chronic idiopathic urticaria? *Allergol Immunopathol (Madr)* 2003;31:209–14.
12. Kuemmerle-Deschner J, Koitschev A, Ummerhofer K, et al. Hearing loss in Muckle-Wells syndrome. *Arthritis Rheum* 2013;65:824–31.
13. Sabroe R, Grattan C, Francis D, Barr R, Kobza B, Greaves M. The autologous serum skin test: a screening test for autoantibodies in chronic idiopathic urticaria. *Br J Dermatol* 1999;140:446–52.
14. Konstantinou GN, Asero R, Maurer M, Sabroe RA, Schmid-Grendle I, Grattan CE. EAACI/GA2LEN task force consensus report: the autologous serum skin test in urticaria. *Allergy* 2009;64:1256–68.

15. Kulthanan K, Jiamton S, Rutnin N, Insawang M, Pinkaew S. Prevalence and relevance of the positivity of skin prick testing in patients with chronic urticaria. *J Dermatol* 2008; 35:330–35.
16. Yadav S, Bajaj A. Management of difficult urticaria. *Indian J Dermatol* 2009;54:275–79.
17. Engin B, Ozdemir M, Balevia A, Mevlitoglu I. Treatment of chronic urticaria with narrowband ultraviolet B phototherapy: a randomized controlled trial. *Acta Derm Venereol* 2008;88:247–51.
18. Greaves M. Chronic urticaria. *J Allergy Clin Immunol* 2000;105:664–72.
19. Maurer M, Rosen K, Hsieh H, et al. Omalizumab for the treatment of chronic idiopathic or spontaneous urticaria. *N Engl J Med* 2013;368:924–35.
20. Kaplan A, Ledford D, Ashby M, et al. Omalizumab in patients with symptomatic chronic idiopathic/spontaneous urticaria despite standard combination therapy. *J Allergy Clin Immunol* 2013;132:101–09.
21. Staubach P, Onnen K, Vonend A, et al. Autologous whole blood injections to patients with chronic urticaria and a positive autologous serum skin test: a placebo-controlled trial. *Dermatology*. 2006;212:150–59.
22. Kocaturk E, Aktas S, Turkoglu Z, et al. Autologous whole blood and autologous serum injections are equally as effective as placebo injections in reducing disease activity in patients with chronic spontaneous urticaria: a placebo controlled, randomized, single-blind study. *J Dermatolog Treat* 2012;23:465–71.

correspondence afp@racgp.org.au